

# J I A C D

The Journal of Implant & Advanced Clinical Dentistry

## "Sticky Bone" Use in Implant Dentistry



**Zirconia Full Arch  
Implant Restoration**

# Utilization of Autologous Concentrated Growth Factors (CGF) Enriched Bone Graft Matrix (Sticky Bone) and CGF-Enriched Fibrin Membrane in Implant Dentistry

Dong-Seok Sohn, DDS, PhD<sup>1</sup> • Bingzhen Huang, MD, PhD<sup>2</sup> • Jin Kim, DDS, MS<sup>3</sup>  
W. Eric Park, DDS<sup>4</sup> • Charles C. Park DDS<sup>5</sup>

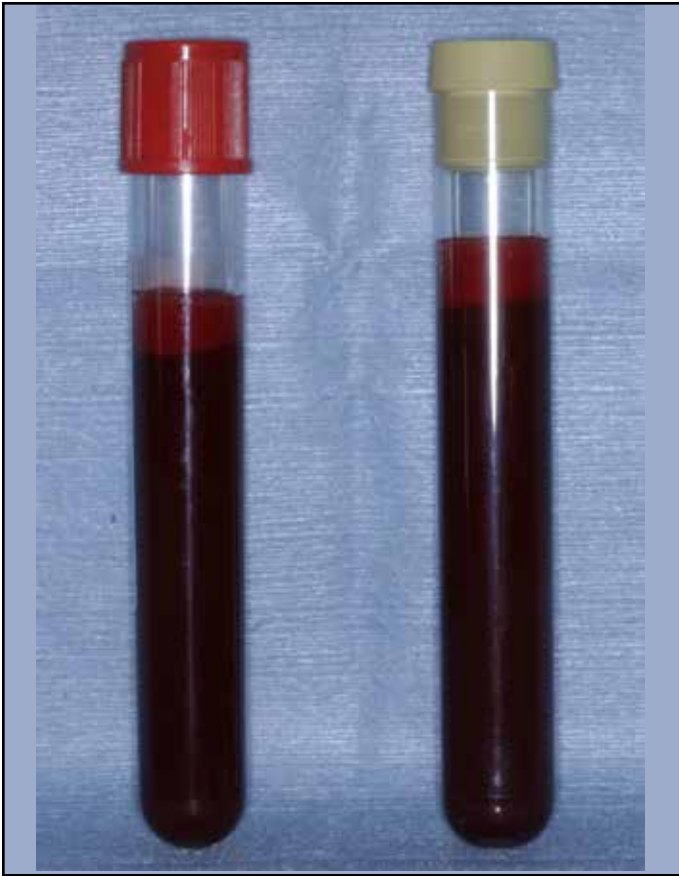## Abstract

**P**latelets are known to release several growth factors which stimulate tissue regeneration. Several techniques for platelet concentrates have been introduced in surgical field for the prevention of hemorrhage and acceleration of tissue regeneration. Platelet rich plasma (PRP) and plasma rich in growth factors (PRGF) belong to the first generation of platelet concentrates. PRP and PRGF require chemical additives such as anticoagulants and thrombin or calcium chloride to induce fibrin polymerization before applying to the surgical site. Platelet rich fibrin (PRF) and concentrated growth factors (CGF), as second generation of platelet concentrate, utilizes patient's venous blood alone to trigger platelet activation and fibrin polymeriza-

tion. PRF and CGF can be used as alternative to traditional barrier membrane over bone graft, therefore acceleration of tissue regeneration is acquired. Unlike PRF using constant centrifugation speed, CGF utilizes altered centrifugation speed to produce much larger, denser and richer fibrin matrix containing growth factors. A new concept of fabricating growth factors-enriched bone graft matrix (also known as "sticky bone") using autologous fibrin glue has been demonstrated since 2010. Sticky bone provides stabilization of bone graft in the defect, and therefore, accelerates tissue healing and minimizes bone loss during healing period. This report presents the method of preparing and utilizing CGF and sticky bone, and clinical cases that support its use.

**KEY WORDS:** Concentrated growth factors, platelet rich fibrin, ridge augmentation, growth factors-enriched bone graft, sticky bone. guided bone regeneration

1. Professor, Department of Dentistry and Oral and Maxillofacial Surgery, Catholic University of Daegu, Republic of Korea
2. Senior Researcher, Harbin Medical University, China
3. Lecturer, UCLA School of Dentistry; Private practice, Diamond Bar, California, USA
4. Lecturer, UCLA School of Dentistry; Private practice, Denver, Colorado, USA
5. Lecturer, UCLA School of Dentistry; Private practice, Orange County, California, USA



**Figure 1:** Patient's venous blood taken from patients' vein in patient's forearm is divided into two types of vacutainers without anticoagulant. Non-coated test tubes (yellow cap) are used to obtain AFG, which will make sticky bone and glass coated test tubes (red cap), is used to obtain CGF layer.

## INTRODUCTION

Implant supported dental restorations have become a major option in the treatment of edentulous alveolar ridge for the past several decades. Extensive loss of alveolar bone presents a complex challenge for reconstruction. Numerous augmentation techniques are currently in use to create sufficient bone volume for reliable placement of endosseous implants in severely resorbed edentulous alveolar ridges.<sup>1</sup> In order to accelerate



**Figure 2:** A specific centrifuge with a rotor turning at alternated and controlled speed from 2,400 to 2,700 rpm for 12 minutes.

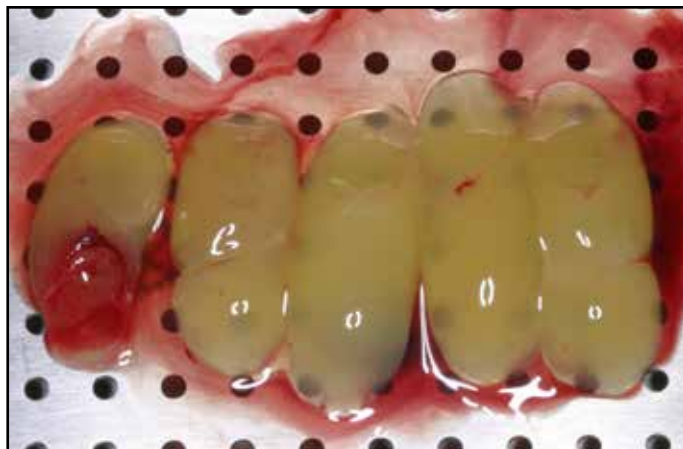healing of bone graft over the bony defect, numerous techniques utilizing platelet and fibrinogen concentrations have been introduced in the literature. Platelet is known to contain high quantities of growth factors, such as transforming growth factors  $\beta$ -1 (TGF $\beta$ -1), platelet-derived growth factor (PDGF), epithelial growth factor (EGF), insulin growth factor-I (IGF-I) and vascular endothelial growth factors (VEGF), which stimulates cell proliferation and up regulates angiogenesis.<sup>2-4</sup>

Platelet rich plasma (PRP) is the first form of autologous platelet concentrate to replace commercial fibrin glue.<sup>5,6</sup> Small amount of PRP is prepared in dental office for use in clinical implant dentistry. Numerous PRP kits, such as the Platelet Concentrated Collection System (PCCS; 3i/ Implant Innovations, Palm Beach Gardens, FL),

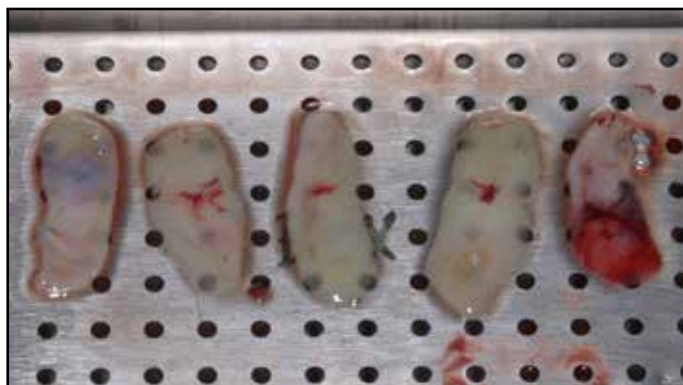

**Figure 3:** Silica coated red cap tube shows three different layers after centrifugation. The most upper layer is platelet poor plasma, and the middle layer is fibrin buffy coat layer represented by a very large and dense polymerized fibrin block containing the concentrated growth factors. The bottom layer is red blood cell layer. Non-coated yellow cap tube shows two different layers. The upper layer is AFG layer and the bottom layer is accumulation of red blood cell is which will be discarded.

SmartPReP (Harvest Autologous Hemobiologics, Norwell, Massachusetts), Curasan PRP kit (Curasan, Pharma GmbH AG, Lindigstrab, Germany) and Placon (Oscotec Co, Chunan, Korea), are available in the current dental market. Preparation methods for all commercially available systems are somewhat similar. Relatively small amount of patient's venous blood (8-10cc)

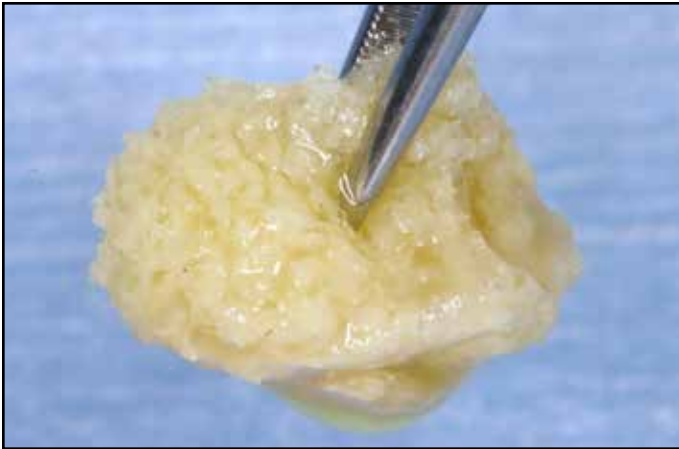


**Figure 4:** CGF layer placed in the sterilized metal storage box before compression. This layer is utilized for sinus augmentation as alternative to bone graft



**Figure 5:** CGF membrane after compressing with metal cover. This membrane is used barrier membrane as alternative to collagen membrane and is used as alternative connective tissue graft for covering exposed root.

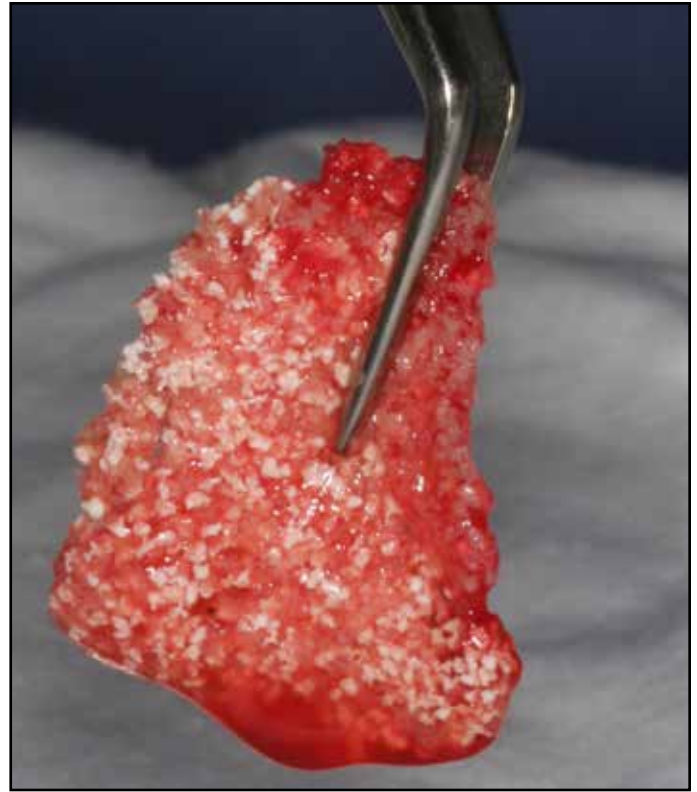is drawn via venipuncture, and the blood is collected in collection tube that contains a chemical anticoagulant. Red cell layer is discarded after first centrifugation, and the buffy coat layer and platelet-poor plasma is collected in a new test tube for second centrifugation. Concentrated platelet with fibrinogen is obtained as a result of the second spin. PRP is mixed with particulate



**Figure 6:** Yellow colored sticky bone mixed with AFG particulate bone powder. It takes 5-10 minutes for polymerization depending on types of bone graft.


bone powder, and bovine thrombin and calcium chloride is added to achieve fibrin polymerization. Anitua's plasma rich in growth factors (PRGF) is obtained by a very similar method as in the PRP protocol. PRGF needs calcium chloride to obtain fibrin polymerization.<sup>7</sup> PRP and PRGF are considered to be the first generation of platelet aggregates, characterized by double centrifugation, and use of chemical additives such as anticoagulants, bovine thrombin, and/or calcium chloride. Their effect on bone regeneration is still controversial.<sup>8</sup>

Second generation of platelet aggregate utilizes patient's venous blood alone. Choukroun's platelet-rich fibrin (PRF) is the first development of such second generation platelet aggregates.<sup>9</sup> Venous blood is drawn from patient's vein and collected in silica-coated Vacutainers without anticoagulants. The Vacutainers are immediately centrifuged at 2,700 rpm for 12 minutes. A natural coagulation of fibrin layer is obtained with separation of the red blood cell layer, platelet-rich fibrin can be easily col-



**Figure 7:** Red colored sticky bone. For acceleration of polymerization of sticky bone, when exudate taken after compression of CGF layer is added, auto-polymerization is usually completed within 1 minute.

lected from the tube. Sacco's concentrated growth factors (CGF) utilizes altered centrifugation from 2,400 – 2,700 rpm for 12 minutes to obtain much larger, denser and richer growth factors fibrin matrix.<sup>10,11</sup> PRF or CGF layers contain concentrated autologous growth factors, but it has limited utilization for ridge augmentation as PRF/CGF layer cannot stabilize particulate or powder bone, unlike the first generation aggregates, PRP/PRGF. The aim of this report is to introduce easy and predictable ridge and sinus augmentation technique utilizing CGF membrane and growth factors-enriched bone graft matrix (Sticky Bone™).



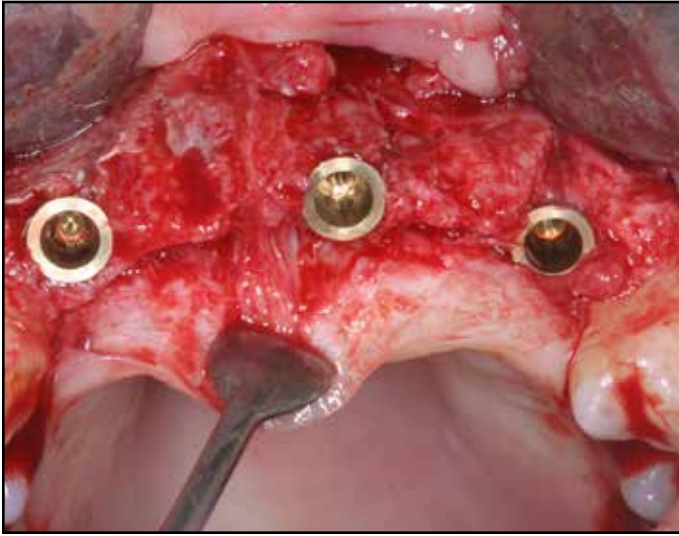
**Figure 8:** SEM image showing strongly interlocked fibrin network of sticky bone.

## THE PREPARATION OF CGF MEMBRANE AND “STICKY BONE”

CGF membrane and autologous fibrin glue (AFG) to make sticky bone is prepared at the same time. Before ridge and/or sinus augmentation surgery is performed, 20-60CC of patient's venous blood is taken from patients' vein in patient's forearm, and the blood is divided to one to two non-coated vacutainers (yellow cap as shown on Fig 1) to obtain autologous fibrin glue (AFG), which will make sticky bone and two to seven glass coated test tubes (red cap as shown on Fig 1) without anticoagulants to obtain CGF layer (Fig 1). The blood in the test tubes is centrifuged at 2400-2700 rpm using specific centrifuge (Medifuge, Silfradent srl, Sofia, Italy or any other compatible devices) with a rotor turning at alternated and controlled speed for 12 minutes (Fig 2). The centrifugation time for AFG varies from 2-12

minutes. To get higher growth factors, the centrifuge is stopped after 2 minute-centrifugation and take AFG tube out of the centrifuge first. The non-coated tube shows 2 different layers. The upper layer is autologous fibrin glue (AFG) layer and red blood cell is collected in bottom layer which will be discarded. The vacant slot is filled with water filled test tube for weight balance and continued centrifugation to prepare CGF. After centrifugation, silica coated tube shows three different layers. The most upper layer is platelet poor plasma, and the middle layer is fibrin buffy coat layer represented by a very large and dense polymerised fibrin block containing the concentrated growth factors. The bottom layer is red blood cell layer (Fig 3). CGF is taken in test tube and placed in the metal storage box and compress with metal cover to convert to CGF membrane (Figs 3-5).

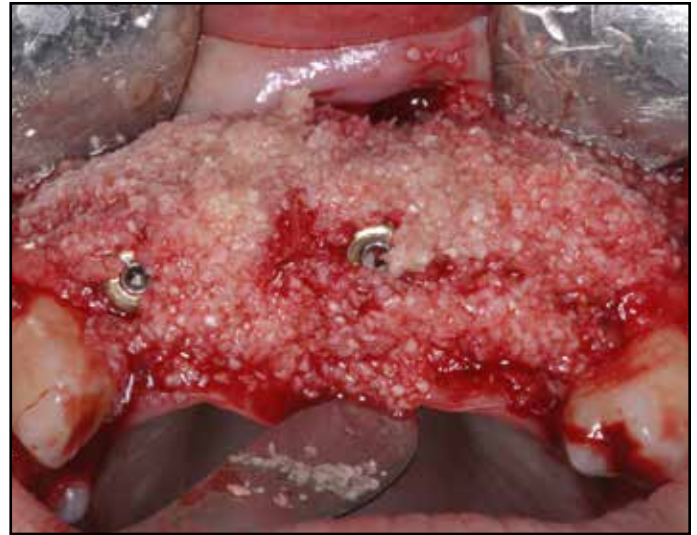The upper AFG is obtained with syringe and mixed with particulate bone powder and allows for 5-10 minutes for polymerization in order to produce sticky bone which is yellow colored (Fig 6). For acceleration of polymerization of AFG, exudate taken in the bottom of metal storage box after compression of CGF layer is added when AFG and particulate bone graft is mixed. The exudate contains growth factors and autologous thrombin in RBC layer, therefore auto-polymerization will be completed very rapidly. The sticky bone mixed with autologous thrombin in RBC layer shows red in color (Fig 7). This sticky bone doesn't migrate even shaking it thanks to strongly interlinked fibrin network, so the bone loss on the defect during healing period is minimized without use of bone tack or titanium mesh (Fig 8).



**Figure 9:** Note horizontal bone deficiency after implant placement. Left site shows more larger deficiency than right edentulous area.

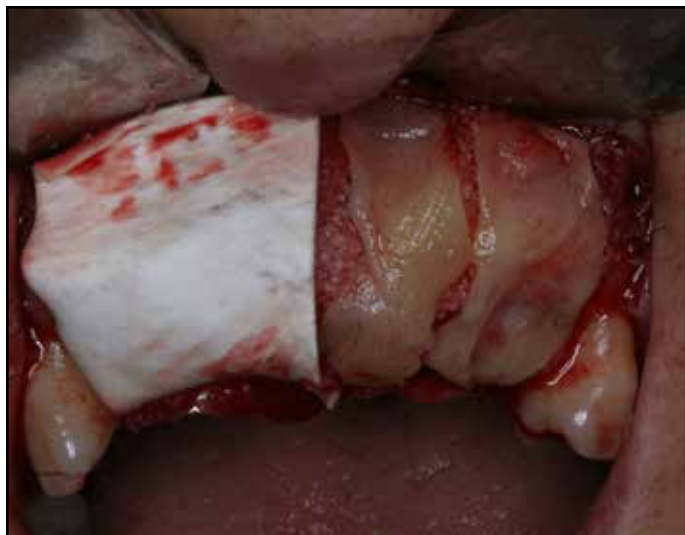### Case report 1: Comparison of CGF Membrane and Collagen Membrane

A 39 year old female patient presented with missing teeth #7, #8, #9, #10. She wanted implant supported fixed restoration. Prophylactic oral antibiotics, Cefditoren pivoxil (Meiact®; Boryung Pharm., Seoul, Korea) 300mg t.i.d. were used routinely, beginning one day prior to the procedure and continuing for five days. Implant site was exposed under local anesthesia with no intravenous sedation. Implants (Biocer implant, OMT GmbH, Lübeck, Germany) were placed at the site of tooth numbers #7, #9 and #11, and horizontal bone deficiency was seen. Mineral allograft (BioTis, Bone Bank, BioTis Co, Seoul) was mixed with exudate taken from compressed CGF and grafted on horizontal bony defect and a collagen membrane (Pericardium, Zimmer Dental, CA) was covered on the right side and two CGF membrane was covered on the left augmented site (Figs 9-11). Tension

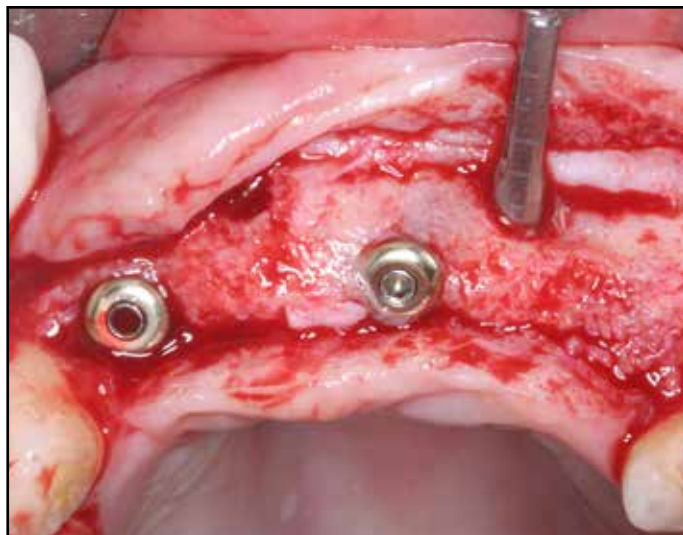


**Figure 10:** Mineral allograft (BioTis, Bone Bank, BioTis Co, Seoul) saturated with exudate taken from compressed CGF was grafted on the bony defect.

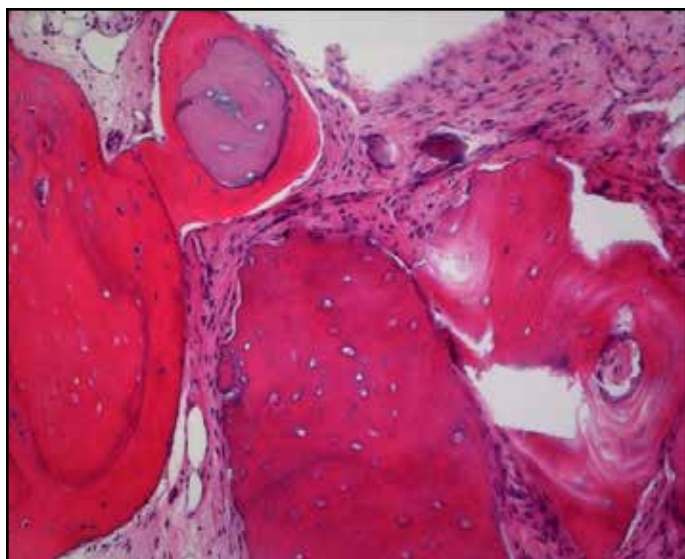
free primary suture was placed. Bone graft site was surgically re-entered after a 6-month healing period, and favorable ridge augmentation was seen at the both augmented site. To compare both augmented sites using collagen membrane and CGF membrane, bone biopsy using 2mm wide trephine bur was taken at the buccal wall of both sites (Fig 12). The specimen was fixed with 4% paraformaldehyde for 24 hours, and washed with 0.1M phosphoric buffered solution and decalcified with 10% formic acid for five days. The specimen was embedded in paraffin (Paraplast®, Oxford, USA), and sliced coronally into serial sections about 5 thick. The specimens were stained with Hematoxylin-Eosin (H-E) stains, and examined under light microscopy to verify newly-formed bone. Both specimens reveals favorable new bone formation along mineral allograft without sign of inflammation (Fig 13, 14). Esthetic final results have been maintained after 2 years follow up (Figs 15-17).



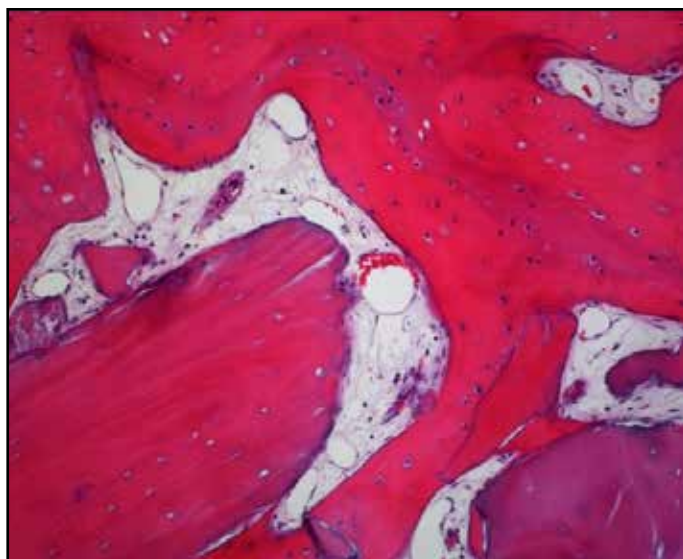
**Figure 11:** A collagen was covered on the right augmented site and two CGF membrane was covered on the left augmented site.



**Figure 12:** Reentry was done after a 6-month healing period. Favorable ridge augmentation was seen at the both augmented site. To compare both augmented sites using collagen membrane and CGF membrane histologically, bone biopsy core using 2mm wide trephine bur was taken at the buccal wall of both sites.

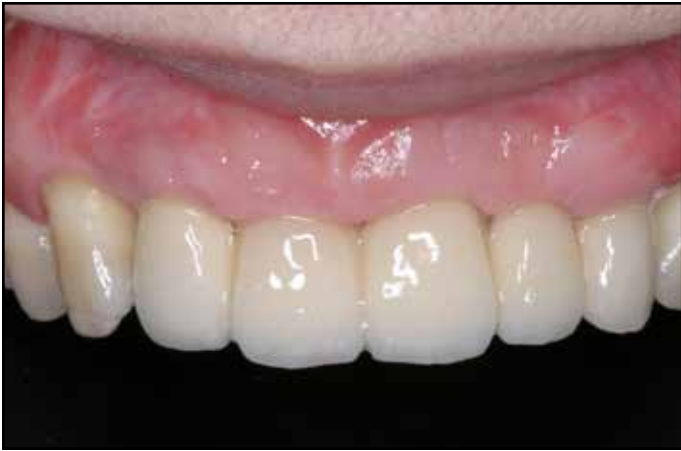

**Figure 13:** Biopsy in left augmented site shows newly formed bone along mineral allograft. Hematoxylin-Eosin (H-E) stains (X100).

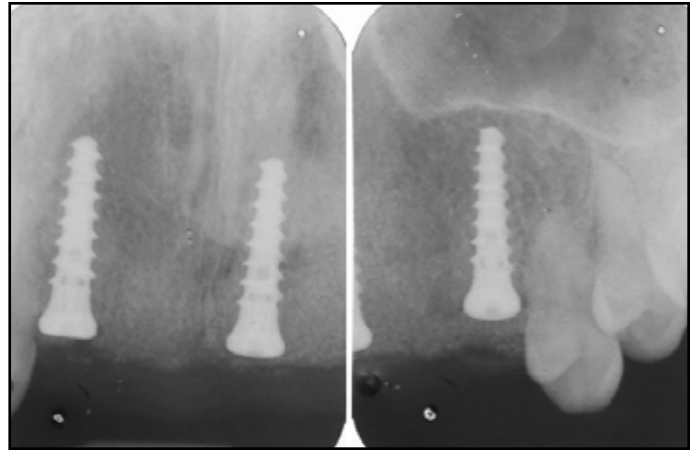


**Figure 14:** Biopsy in right augmented site shows favorable new bone formation along mineral allograft without sign of inflammation.. Hematoxylin-Eosin (H-E) stains ( X100).

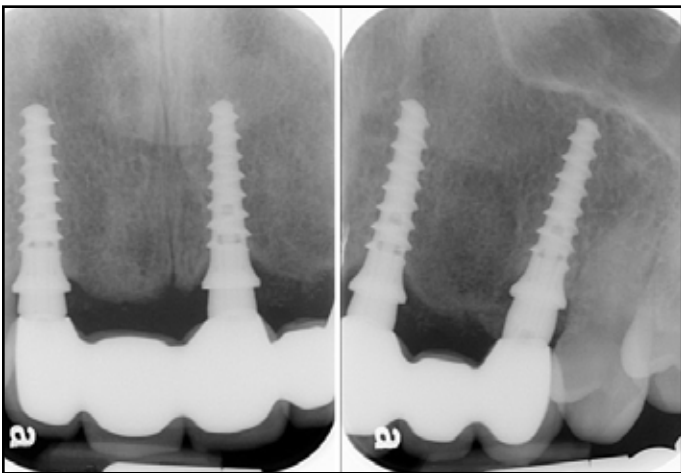




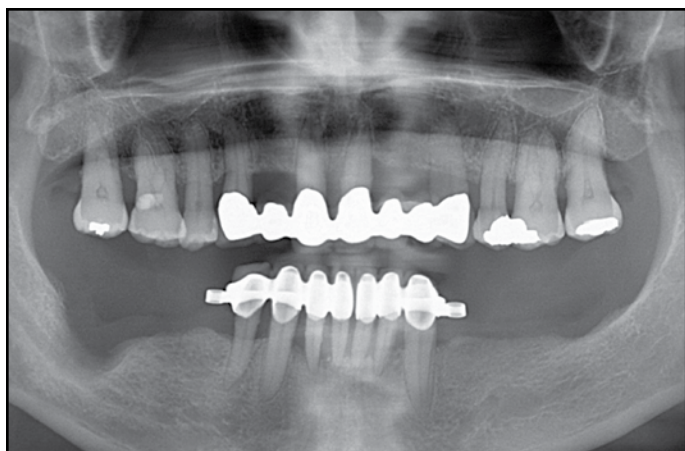
**Figure 15:** Esthetic final result in 2 years follow up.



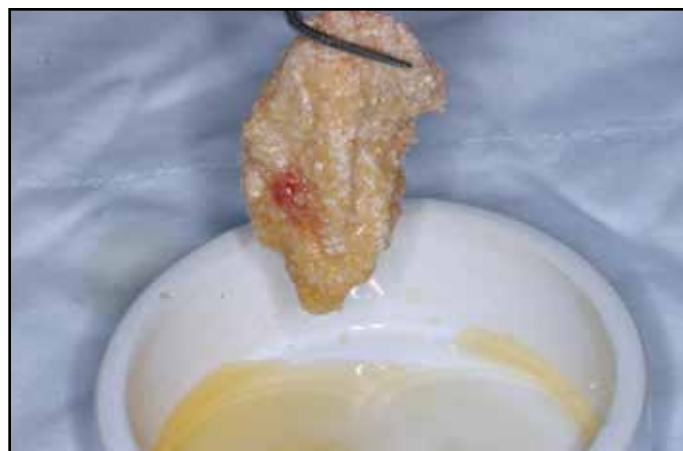**Figure 16:** A postoperative periapical radiograph.



**Figure 17:** A periapical radiograph in 2 years function reveals stable bone maintenance.



**Figure 18:** A plain radiograph reveals severe vertical bony deficiency on the right posterior mandible.

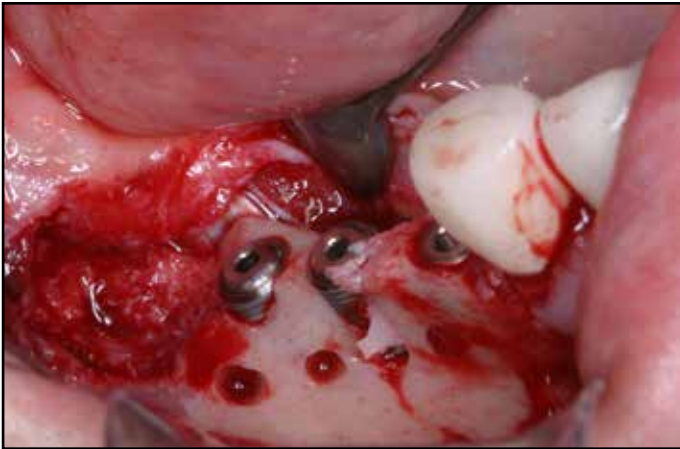


**Figure 19:** Prepared sticky bone using bovine and mineral allograft.

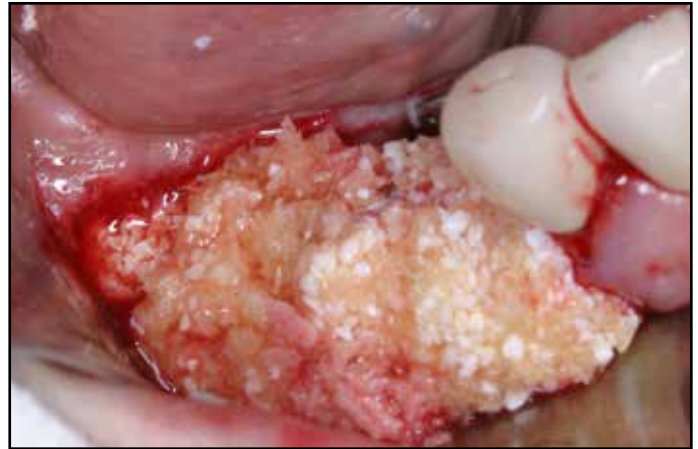### Case 2: Three Dimensional Ridge Augmentation using Sticky bone with/without Titanium Mesh

A 45-year-old male patient with a complaint of masticatory difficulty was referred from private dental clinic for the ridge augmentation and implant placement. Radiographic and clinical examination revealed severe vertical and horizontal ridge resorption on the right mandibular edentulous ridge and severe horizontal ridge deficiency on the left the mandibular edentulous ridge (Fig 18). Sticky bone was prepared as described above before surgery (Fig 19). The surgery was performed under the local anesthesia through maxillary block anesthesia by using 2% lidocaine that includes 1:100,000 epinephrine. Full thickness mucoperiosteal flap was elevated to expose the both implant sites. Right edentulous posterior area showed severe vertical defect and narrow (2-3mm wide) alveolar ridge. Three implants (Dentis implant Co, Daegu, Korea) were placed at the sites of tooth numbers #29, #30, and 31 with good stability. Exposure of implant surface was shown at the site of #30 and #31. Prepared

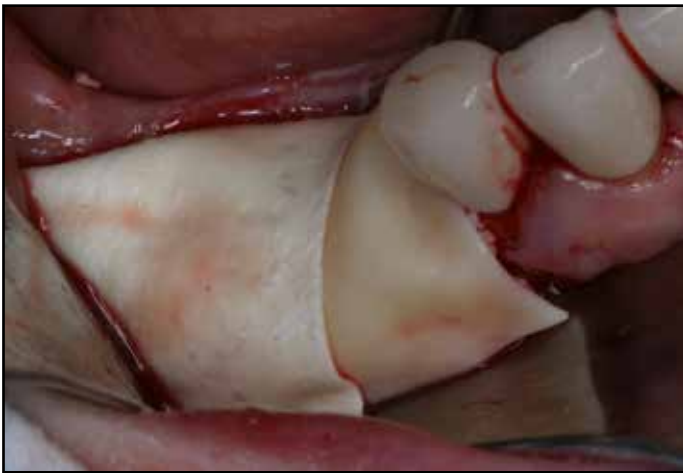sticky bone using bovine bone (Biocera, Oscotec Co, Chunan, Korea) and mineral allograft (Puros allograft, Zimmer Dental, CA) was grafted over the exposed implant surface and bony defect for 3-dimensional ridge augmentation, and resorbable collagen membrane (Pericardium, Zimmer Dental, CA) alone was covered over the bone graft (Figs 19-22). The left edentulous ridge revealed severe horizontal deficiency. Three implants were placed at the sites corresponding to tooth numbers #18, #19, and 20 with good stability, and severe exposure of implants was shown. Particulate bone graft was placed on the defect and titanium mesh (Neo implant Co, Seoul, Korea) was covered to stabilize particulate bone graft. Three CGF membrane was covered over the bone graft and mesh (Figs 23-25). Implants were exposed after 4months healing. Favorable 3-dimensional ridge augmentation was observed on the right area even titanium mesh was not used because sticky bone didn't migrate during healing period. Favorable horizontal ridge augmentation was observed on the left site. The patient came back to her dentist for prosthetic restoration (Figs 27-29).



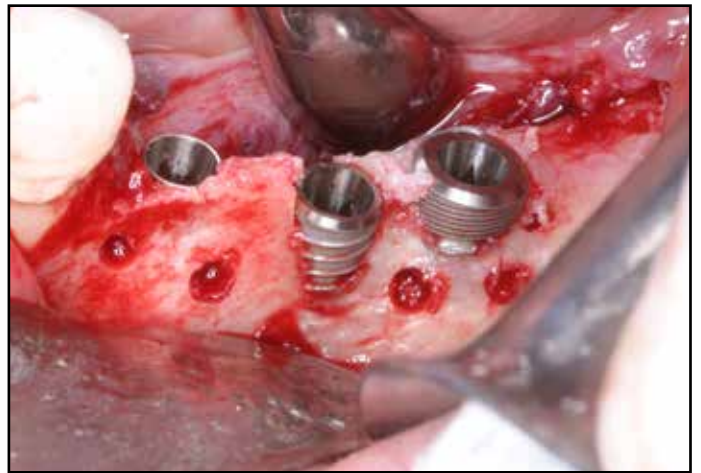**Figure 20:** Note severe exposure of implant surface after implant placement and vertical bone defect.



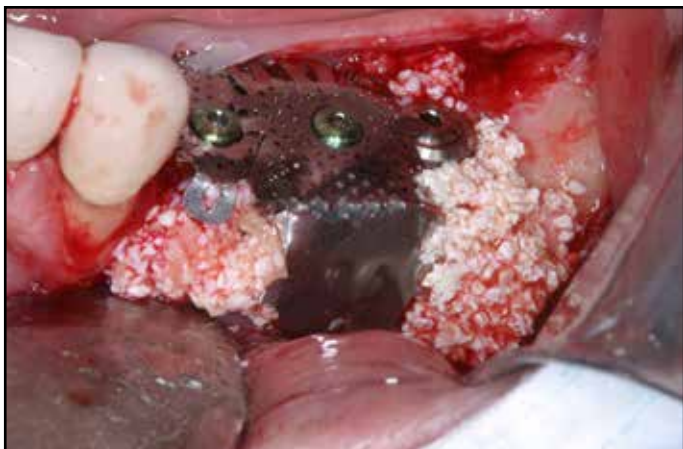**Figure 21:** Sticky bone was grafted on the exposed implant surface and bony defect for 3-dimensional ridge augmentation.



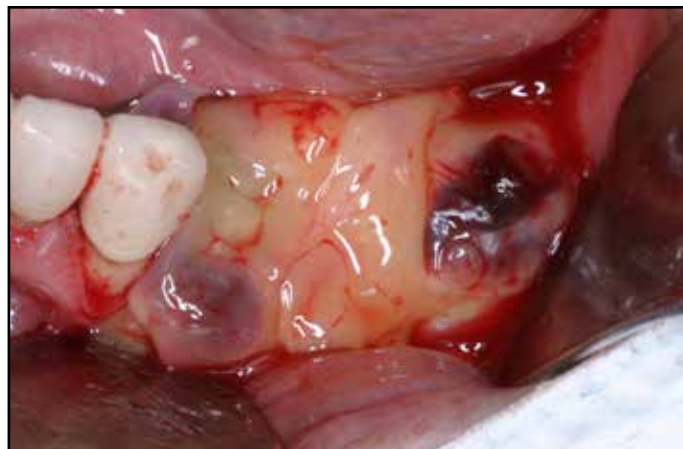**Figure 22:** A resorbable collagen membrane alone was covered over the bone graft without additional bone stabilization procedure.



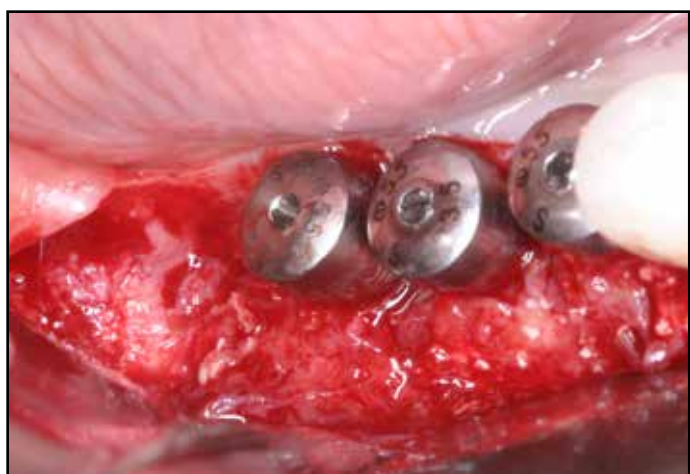**Figure 23:** Note severe exposure of implant surface on the edentulous left posterior mandible.



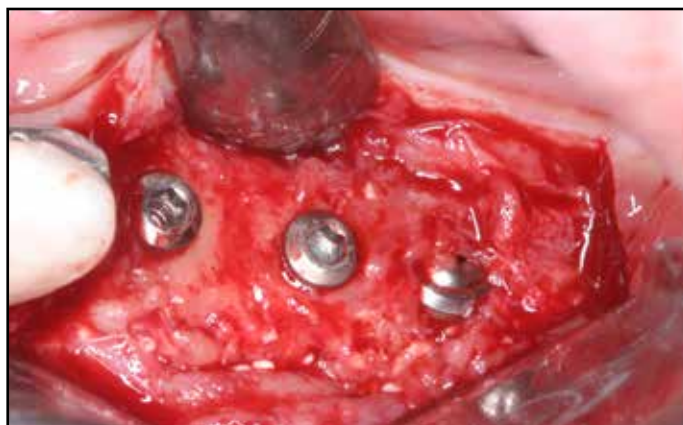
**Figure 24:** Sticky bone was not prepared, so particulate bone graft was placed on the defect and customized titanium mesh (Neo implant Co, Seoul, Kora) was utilized to stabilize particulate bone graft.



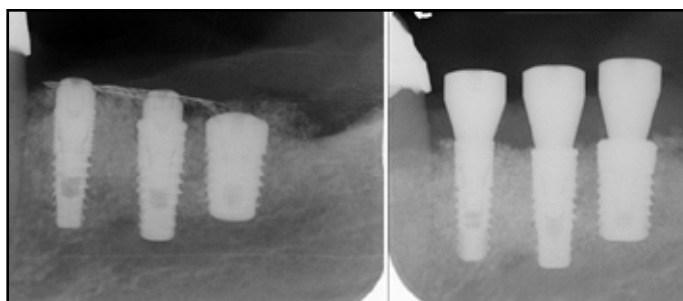
**Figure 25:** Three CGF membrane was covered over the bone graft and mesh to accelerate tissue regeneration.



**Figure 26:** Note favorable 3-dimensional ridge augmentation after 4 months healing on the right site. Sticky bone didn't migrate even grafted for three dimensional augmentation without use of additional bone graft stabilization materials.



**Figure 28:** A postoperative periapical radiograph (left) and radiograph (right) after uncovering on the right site.

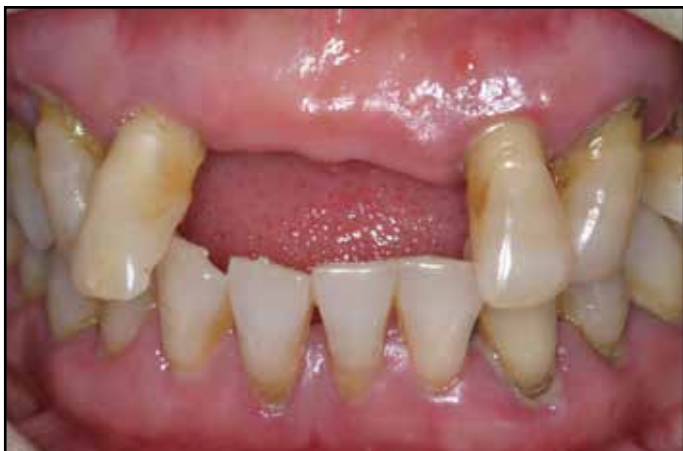

**Figure 29:** A postoperative periapical radiograph (left) and radiograph (right) after uncovering on the right site.

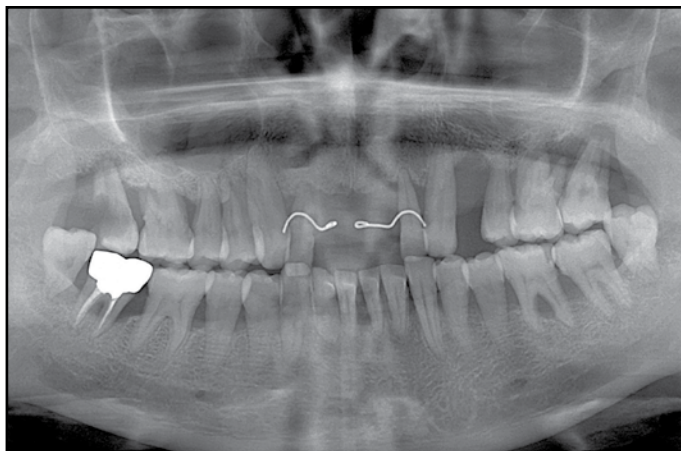
### Case 3: Minimally Invasive Horizontal Ridge Augmentation using Sticky Bone and Tunnel Technique

A 49 year old female patient visited at our department with complaint of masticatory difficulty and esthetic problem. She has suffered from chronic periodontitis in whole dentition and showed the missing of upper two central incisors (Figs 30, 31). The hopeless upper right and left lateral incisor and left canine were extracted under local anesthesia. Three implants (MIS Implant, Israel) were placed immediately. Labial fenestration defect was verified in the all implant sites through the vertical releasing incision which was made in buccal mucosa adjacent to implant site. Sticky bone prepared with bovine bone (Biocera, Oscotec Co, Chunan, Korea) and mineral allograft (Puros allograft, Zimmer Dental, CA) was grafted over the exposed implant surface through the vertical incision. Collagen membrane or titanium mesh was not used to stabilize bone graft (Figs 32-35). After closing of incision area in edentulous anterior maxilla, hopeless upper right second premolar and first and second molar were extracted in order to perform sinus aug-

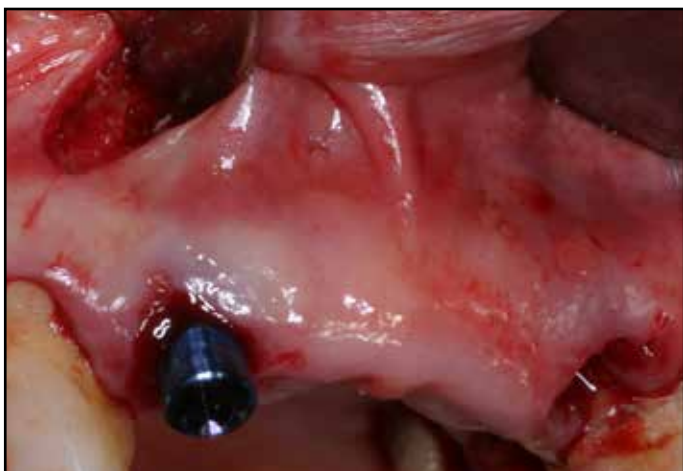mentation and simultaneous implant placement. Osteoinductive replaceable bone window was prepared with a thin bladed saw insert (S-Saw, Bukboo Dental Co., Daegu, Korea), connected to piezoelectric devices (Surgybone®, Silfradent srl, Sofia, Italy) to access sinus cavity. The bony window was detached from sinus membrane and sinus membrane elevation was performed carefully. Four pieces of CGF was inserted in the new compartment under the elevated sinus mucosa and three implants were placed immediately at the sites corresponding to tooth numbers #13, #14 and #15. The detached bony window was repositioned and particulate bovine bone was grafted in the extract defect and collagen membrane was covered over the bone graft to prevent soft tissue invasion and stabilize particulate bone graft (Figs 36-41). Immediate temporary restoration on anterior implant was delivered on the next day. Final ceramic restoration was cemented in all implant sites after 6 months healing. The cross sectional image of cone beam computed tomogram shows stable bone augmentation over the exposed implant surface after 1 year loading (Figs 42-46).



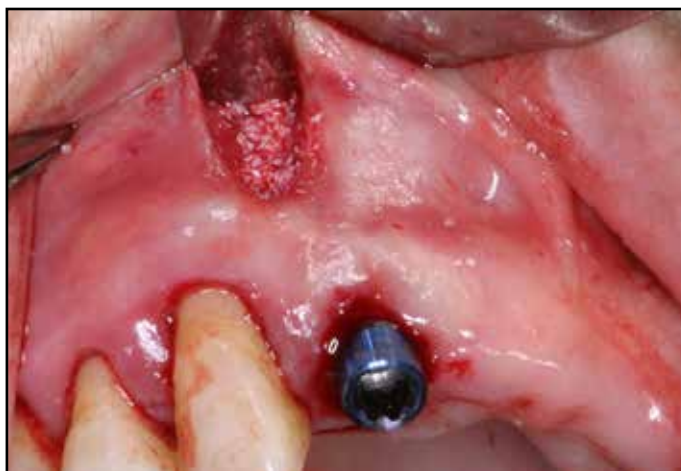**Figure 30:** Preoperative intraoral view reveals the missing of upper two central incisors and chronic periodontitis in whole dentition.



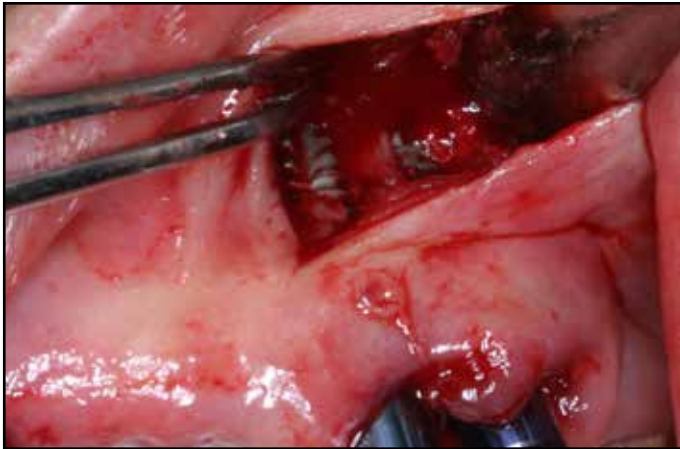
**Figure 31:** Preoperative intraoral image reveals chronic periodontitis with severe bone resorption in entire dentition.



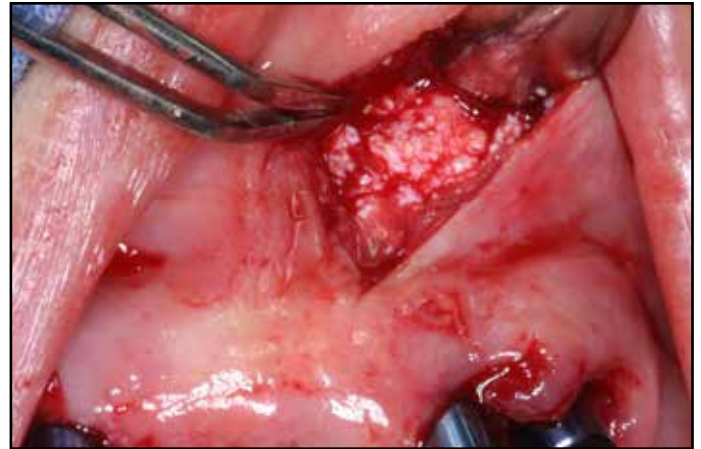
**Figure 32:** A pain radiograph reveals severe alveolar bone resorption in entire dentition.



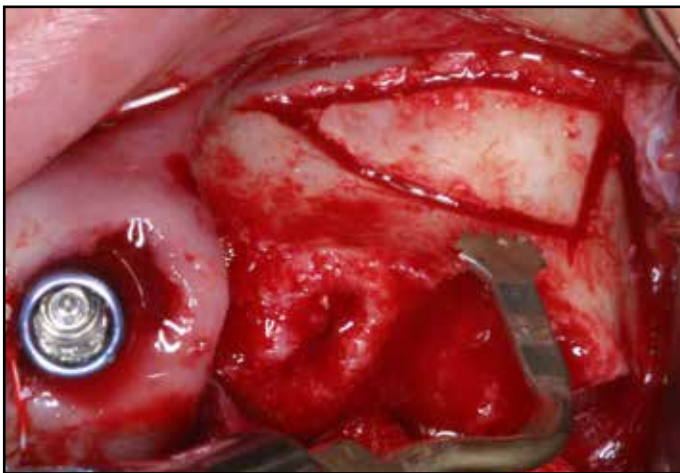
**Figure 33:** Implants were placed immediately after extraction of upper right and left lateral incisor and left canine. Dehiscence defect was detected on implant site corresponding to right lateral incisor.



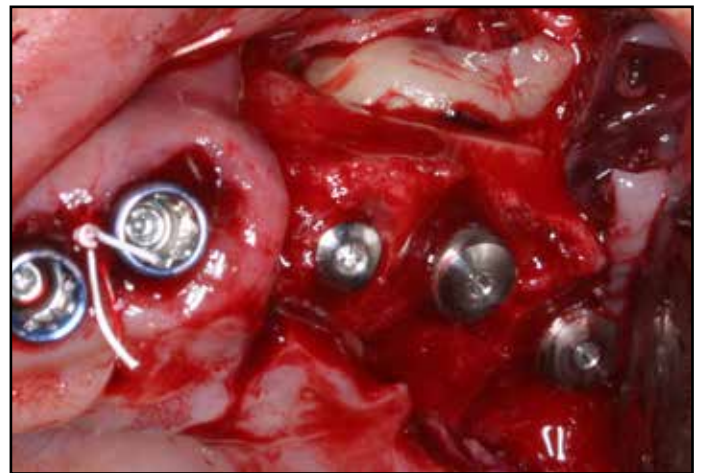
**Figure 34:** Labial fenestration defect was verified in implants corresponding to tooth number #10 and #11.



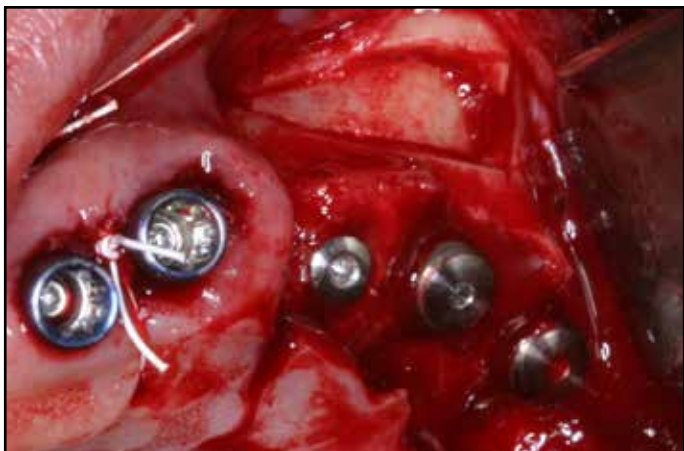**Figure 35:** Prepared sticky bone was grafted over the exposed implant surface by tunnel technique. Any barrier membrane was not utilized.



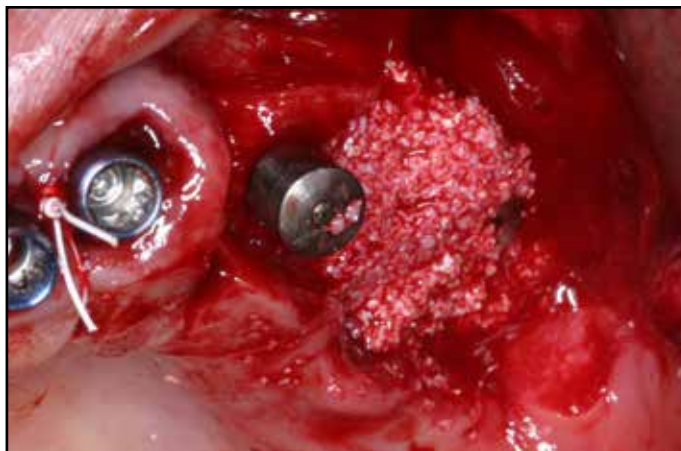**Figure 36:** After extraction of hopeless upper right second premolar and first and second molar, laterally approached sinus augmentation was performed. Osteoinductive replaceable bone window was prepared with a thin bladed saw insert to access sinus cavity.



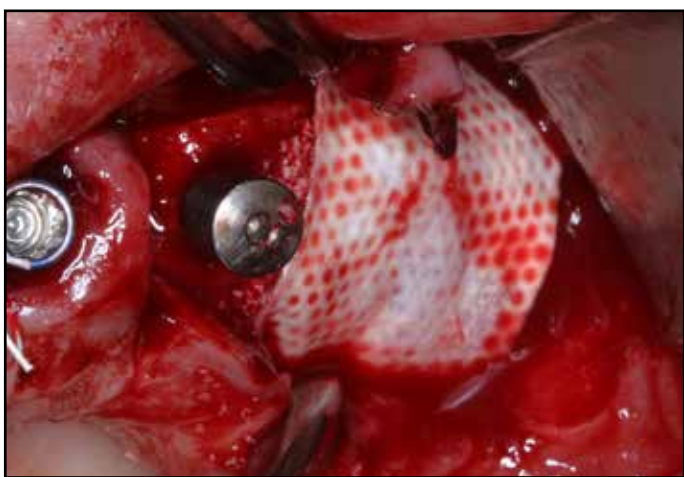**Figure 37:** Sinus membrane was elevated carefully after detachment of the bony window.



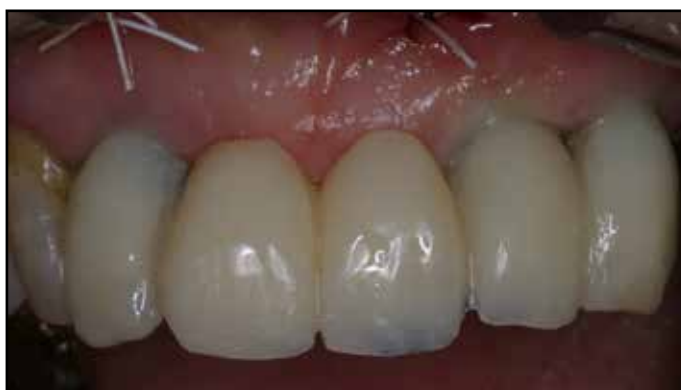**Figure 38:** Four pieces of CGF was inserted in the sinus and implants were placed simultaneously at the site of tooth numbers of #13, #14 and #15. The detached bony window was repositioned.



**Figure 39:** Particulate bovine bone was grafted in the extraction defect and collagen membrane was covered over the bone graft.

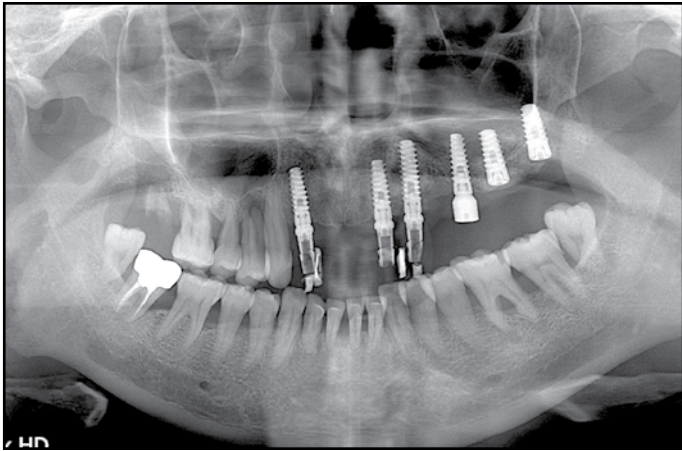


**Figure 40:** Particulate bovine bone was grafted in the extract defect and collagen membrane was covered over the bone graft to prevent soft tissue invasion and stabilize particulate bone graft.

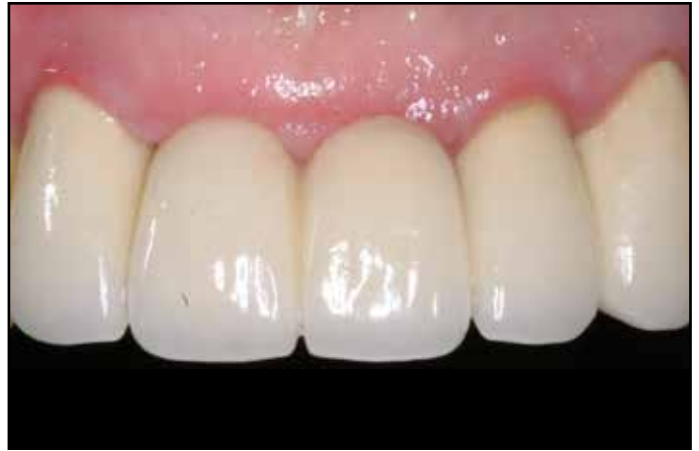

**Figure 41:** Immediate temporary restoration on upper anterior implant sites.

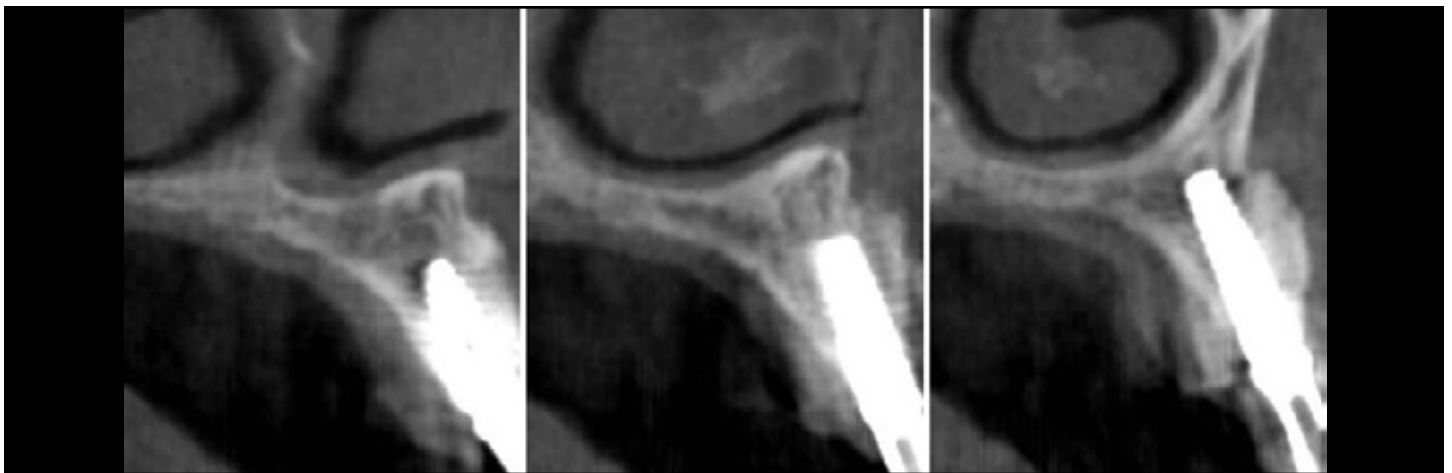




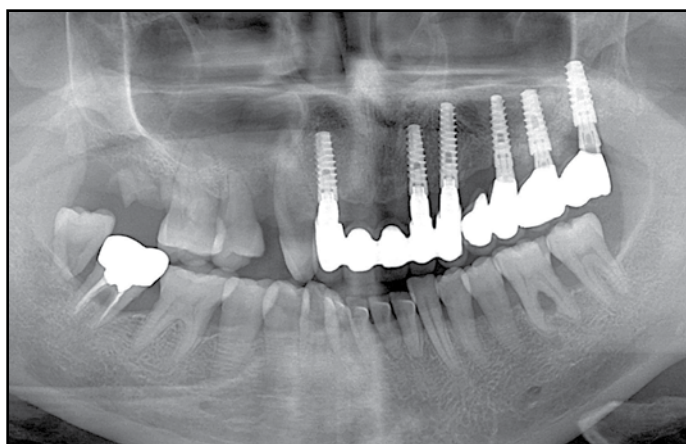
**Figure 42:** Postoperative radiograph.



**Figure 43:** Final ceramic restoration was cemented after 6 months healing.



**Figure 44:** The cross sectional image of CBCT reveals stable bone augmentation over the exposed implant surface after 1 year loading.



**Figure 45:** A plain radiograph after 1 year in function. Note sinus augmentation with CGF alone.

## DISCUSSION

Platelets are known to release high quantities of growth factors such as platelet-derived growth factor (PDGF), transforming growth factor- $\beta$ 1 (TGF- $\beta$ 1) and  $\beta$ 2 (TGF- $\beta$ 2), fibroblast growth factor (FGF), vascular endothelial growth factor (VEGF), and insulin-like growth factor (IGF), which stimulate cell proliferation, matrix remodeling, and angiogenesis.<sup>12</sup> Several techniques to collect platelet aggregate have been utilized to accelerate tissue healing in dental and medical field.<sup>6-10</sup> Choukron's PRF and Sacco's CGF are recently developed platelet aggregation. These two methods collect leukocyte and platelet rich fibrin gel using a natural coagulation process. Compared to PRP and PRGF, PRF and CGF are simple to make and doesn't require any synthetic or biomaterials, such as bovine thrombin and calcium chloride, to make gel condition. So it is free from the risk of cross-contamination.<sup>13</sup> Fibrin rich gel is known to release slowly growth factors such as transforming growth factor, platelet-derived growth factor and vascular endothelial growth factor and accelerates new bone formation when it mixed with bone graft in the maxillary sinus.<sup>14,15</sup> You et al. reported that platelet rich fibrin gel can induce higher bone to implant contact than platelet rich plasma in bony defect around dental implant.<sup>16</sup>

Unlike PRF using constant centrifugation, CGF utilize altered centrifugation speed from 2,400-2,700 rpm to isolate much larger, denser and richer in growth factors enriched fibrin matrix.<sup>11</sup> As alternative to bone substitutes, growth factors enriched fibrin gel revealed active new bone formation in the maxillary sinus without complication of postoperative infection.<sup>17-21</sup> PRF and CGF in a com-

pressed membrane-like form has also been used as a substitute for commercially available collagen barrier membranes in guided bone regeneration to improve tissue healing.<sup>22,23</sup>

Atrophic alveolar ridge is a challenging site to place implant. Guided bone regeneration (GBR) using bone graft and barrier membrane is a well-established technique for augmentation of atrophic alveolar ridges.<sup>24-26</sup> For successful GBR, stability of bone graft, space maintenance, angiogenesis, and tension free primary suture are essential.<sup>26,27</sup> Space maintenance with particulate bone graft should be provided during healing period. However particulate bone graft is easily migrated when grafted on the large horizontal/vertical bone defect. To reconstruct large one or two wall bony defect or for the 3-dimensional ridge augmentation, bone tack on the collagen membrane or titanium mesh is required to contain particulate bone graft during healing but these procedures are surgically time consuming and technique sensitive. In addition, the early exposure of titanium mesh causes bone loss and infection which causes failure of bone augmentation.<sup>28,29</sup> For solid space maintenance in the severely atrophic alveolar ridge, block bone graft procedure is widely accepted but this technique has several disadvantages such as early exposure of bone graft, neurosensory disturbance, increased patient's postoperative discomfort and surgical cost, delayed surgical time and additional surgery from donor site.<sup>30,31</sup>

As alternative to titanium mesh or block bone procedure, sticky bone was introduced in 2010 by authors.<sup>32</sup> Sticky bone is biologically solidified bone graft which is entrapped in fibrin network. Sticky bone graft doesn't scatter even