

Sandwich Technique of Socket Preservation using Concentrated Growth Factor and Tricalcium Phosphate and an Immediate Interim Prosthesis with a Natural Tooth Pontic: A Case Report

M Hemalata¹, D Jayanthi², Lalith Vivekanand³, Ghazala Ahmed Shafi⁴, Vinnakota Keerti⁴

¹Head and Professor, Department of Periodontics, M.R. Ambedkar Dental College and Hospital, Bengaluru, Karnataka, India, ²Professor, Department of Periodontics, M.R. Ambedkar Dental College and Hospital, Bengaluru, Karnataka, India, ³Reader, Department of Periodontics, M.R. Ambedkar Dental College and Hospital, Bengaluru, Karnataka, India, ⁴Post Graduate Student, Department of Periodontics, M.R. Ambedkar Dental College and Hospital, Bengaluru, Karnataka, India

ABSTRACT

Sudden tooth loss in the esthetic zone impairs patients physically and emotionally. The extraction socket preservation technique conserves the alveolar architecture and prevents hard and soft tissue collapse that minimizes the necessity for future augmentation procedures. Socket preservation using platelet-rich fibrin (PRF) along with bone grafts enhances osteogenic differentiation and bone repair. After socket preservation, replacement of the missing tooth can be considered. Irrespective of the final treatment, the first line of treatment would be to provisionally restore the patient's esthetic appearance at the earliest while functionally stabilizing the compromised arch. Using the patient's own natural tooth as a pontic offers the benefits of being the right size, shape and color, economical and fulfills functional and psychological requirements of the patient. This article describes socket preservation using a concentrated growth factor (CGF) sandwich technique using alloplasts with autologous PRF for preserving a future implant site. Simultaneously involves the use of resin bonded, wire retained natural tooth as a pontic to restore the edentulous space until the final restoration. The soft and hard tissue healing was satisfactory clinically and radiographically post 6 months of therapy. Furthermore, the natural tooth pontic (NTP) has served as a satisfactory interim restoration. The same NTP can be used as a provisional prosthesis during the two-stage implant procedure. CGF sandwich technique is an effective technique for socket preservation, along with an NTP, which aids in preserving hard and soft tissues at the future implant site.

Keywords: Concentrated growth factor, Interim restoration, Natural tooth pontic, Platelet-rich fibrin, Socket preservation

Corresponding Author: Ghazala Ahmed Shafi, No. 7/1, First Floor, 12th Cross Road, Jayamahal Extension, Bengaluru - 560 046, Karnataka, India. Phone: +91-9880242334. E-mail: drghazala_ahmed@hotmail.com

INTRODUCTION

The sudden loss of an anterior tooth is a catastrophic event for a patient.¹ Most of the patients demand immediate treatment because they usually suffer from psychological trauma and their social life gets affected by compromised esthetics.² The clinician should have a wide arsenal of treatment options to encounter the compromised esthetics. This may include the preservation of the socket for future rehabilitation and immediately restore/replace the missing tooth.

Whether due to caries, trauma, advanced periodontal disease, tooth extraction, or subsequent healing of the extraction socket, all commonly result in osseous deformities of the alveolar ridge including reduced height and width of the residual ridge.³ The subsequent ridge deformity poses a challenge to the rehabilitation process.⁴

Apart from approaches to preserve hard tissue, the ability to preserve soft tissue contour is also an important consideration in the esthetic zone, particularly in cases

with thin labial plate.² Site preservation through socket grafting will help to optimize bony fill within the extraction socket, thereby maintaining vertical bone height and help stabilize the marginal tissues.⁵

Various treatment options available for socket preservation include packing of grafting materials (either particulate or block grafts) into the socket, using membranes, use of concentrated growth factors (CGF), and closure of socket by raising a mucoperiosteal flap. Socket preservation using a combination of bone graft and CGF/platelet-rich fibrin (CGF/PRF) provides for a scaffold, to support the blood clot, provides growth factors, assists healing, prevents collapse of socket walls, and encourages natural way for bone regeneration.⁶

The main reasons for socket grafting are:⁷

- To prevent future bone loss and ridge resorption
- In type 2 or type 3 alveolar sockets post extraction, to support the labial plate of bone⁸
- Support of adjacent teeth and implants
- Planning for future options such as implants or a fixed bridge
- Avoidance of additional surgeries for implant site development.

Replacement of the missing tooth can be temporary, semi-temporary, or permanent in nature.⁹ The various treatment options for a single missing tooth includes single tooth implants, conventional fixed partial dentures, and a removable partial denture, all of which require multiple visits to achieve desirable results.¹⁰ Alternatively, replacing a missing tooth in a single visit can be made possible by utilizing an acid etch bridge technique, in which a fiber reinforced composite or even the patient's own natural tooth can be used for replacement.^{3,11}

Use of patient's own natural tooth as a pontic and bonding it to adjacent teeth is more conservative, less time consuming, and economic, offers the benefits of being the right size, shape, and color, and fulfills functional and psychological requirements of the patient.¹²

Selection criteria for this tooth replacement approach include:

- A patient who requires an extraction in an esthetic area and desires an immediate replacement
- A patient who desires an immediate, minimally invasive approach
- A patient with no parafunctional habits such as bruxism
- To attain favorable soft tissue contour before implant placement/loading
- To maintain the arch integrity
- In patients with a contraindication for an FPD
- Cost considerations.¹³

The current article describes a clinical case of socket preservation by CGF sandwich technique (CGFST) using PRF and tricalcium phosphate (TCP) and fabrication of a natural tooth pontic (NTP) for an immediate replacement of periodontally compromised 11, following an atraumatic extraction.

CASE REPORT

A male patient aged 42 years, reported to the Department of Periodontics, M.R. Ambedkar Dental College and Hospital, with the chief complaint of loosening of his upper right central incisor. The medical history of the patient revealed that he is a known asthmatic since 4 years and is on medication for the same. His dental history revealed an episode of trauma with respect to upper right central incisor.

On clinical examination, the patient was diagnosed to have chronic localized periodontitis. The maxillary right central incisor (11) was partially extruded with Grade III mobility and class III gingival recession. Radiographic evaluation (intraoral periapical radiography - paralleling cone technique) revealed poor bone support (i.e., only at the apical third) in relation to 11. The left central incisor and the right lateral incisor had healthy periodontium with adequate bone support, caries free, and good esthetic appearance.

Correlating the periodontal status, radiographic findings, and clinical appearance of the tooth, it was decided to extract 11. Replacement options for the resultant edentulous space were discussed with the patient. The patient was unwilling to lose his tooth and was concerned about esthetics immediately after extraction.

A fixed partial denture was not indicated because of the required extensive tooth preparation and probable damage to pulp tissue. The patient preferred a fixed prosthesis rather than a removable one. Moreover, due to the compromised hard and soft tissue, immediate implant-supported prosthesis was not a feasible replacement option.

Therefore, the socket was preserved for further implant therapy, by a CGF sandwich technique using PRF and TCP. Simultaneously, an immediate chair-side wire retained resin bonded fixed partial denture, using a natural tooth with an ovate contact surface was the treatment of choice. The patient was duly informed about possible limitations and outcome of the procedure.

Preoperative Analysis

Length of the NTP required was predetermined on a study cast of the patient by measuring the gingival level

to the incisal edge (of the adjacent central incisor) plus 3 mm so that it could be extended into the alveolar socket to shape the gingivo-proximal tissue level and preserve the papilla.¹¹

Clinical Procedure

- Atraumatic tooth extraction: After formulating the treatment plan, the maxillary right central incisor was extracted atraumatically under local anesthesia using a periosteal elevator. The periosteal elevator was used to gradually sever the periodontal ligament (PDL) around the tooth and then the luxated tooth was simply removed from the mouth using forceps. The extracted tooth was immersed in normal saline and the remaining soft tissue removed from the surface.
- Socket debridement: The extraction socket was then thoroughly debrided. The socket walls were debrided using a surgical spoon curette. This was done slowly, and all remnant PDL tissue was removed.
- Socket preservation using CGFST: It was decided to do socket preservation in relation to the extracted tooth, using a sandwich technique. This included first gently packing the apical third of the socket with PRF, next packing the middle and coronal third of the socket with a mixture of PRF and TCP graft, and finally covering the socket with a PRF membrane. The membrane was tucked into the socket so as to cover the graft and contain it within the socket as the healing takes place (Figure 1).
- Cross-over sutures placed: To adapt the marginal soft tissues over the barrier membrane, cross-over sutures using 5-0 resorbable suture material were placed.
- Replacement of edentulous space with NTP:
 - The crown was separated from the root, using an airtor hand piece and a diamond bur (ISO No. 314). The apical opening of the pulp canal was cleaned, pulp extirpated and sealed with GIC.
 - An ovate pontic was designed for the apical area to facilitate cleaning and to give an emergence profile to the NTP. A high, smooth surface area was then achieved at the apical area of the NTP with diamond finishing instruments.
 - Two grooves were made mesiodistally on the palatal surface of the crown (1st groove - junction of the incisal and middle third; 2nd groove - junction of the middle, and the cervical third), and the pontic was stabilized in the extraction socket with two 0.001" braided stainless steel wires, embedded into the prepared grooves using composite resin and splinted to two adjacent teeth on either side. The proposed technique not only improves the stability of the pontic but

also prevents rotatory movements of the pontic around all axis of rotation.

- Occlusal adjustments were then made using articulating paper and diamond finishing burs.
- The patient was given the required oral hygiene instructions.

This will serve as a provisional restoration, to help maintain gingival architecture for the final prosthesis, while simultaneously meeting the high esthetic demands of the patient. The patient was recalled after 1 month, to assess the health of the soft tissues in the extraction socket; and later, after 3 months and 6 months, to assess the hard tissue healing in the extraction socket (Figures 2-22).

DISCUSSION

The present era of dentistry relies extensively on esthetic principles because of increasing patient demands.¹⁴ Immediate replacement of the extracted anterior tooth has to be given due consideration for better esthetics, to fulfill patient's needs and restore function to a certain extent.¹⁵ This case report describes a simple, economical, and quick method to improve the esthetics of patients having an extruded anterior tooth with a poor prognosis due to trauma and extensive bone loss, by utilizing socket preservation technique and an NTP.

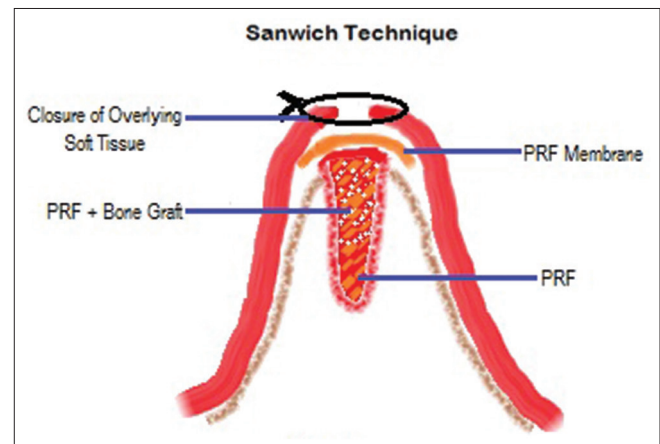


Figure 1: Sandwich technique

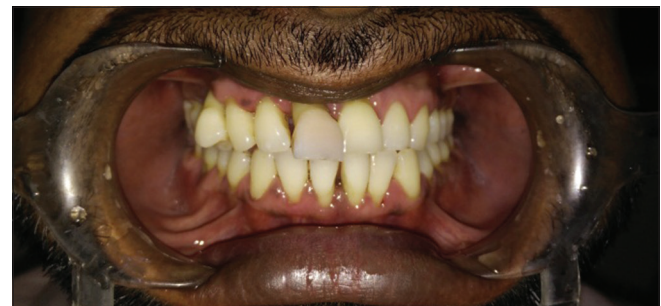

Figure 2: Pre-operative view

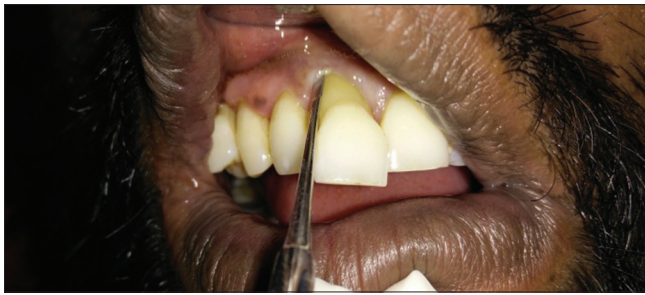

Figure 3: Atraumatic extraction using periosteal

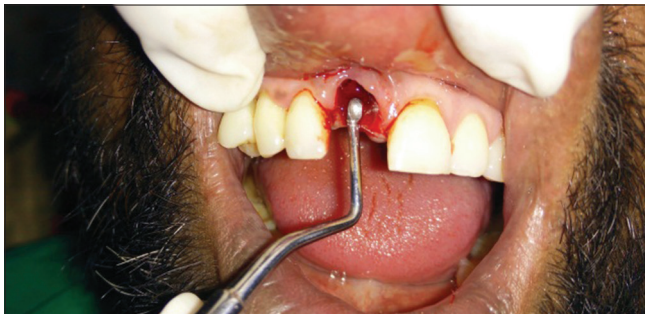

Figure 4: Curettage of the socket

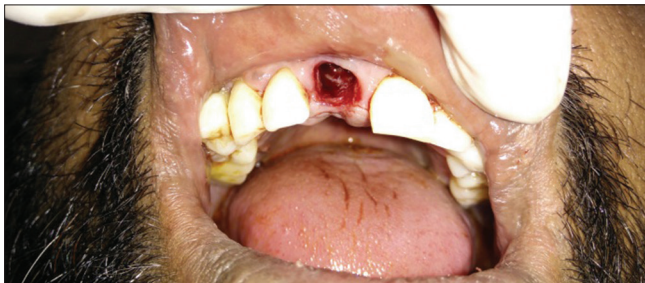

Figure 5: Extraction socket after curettage

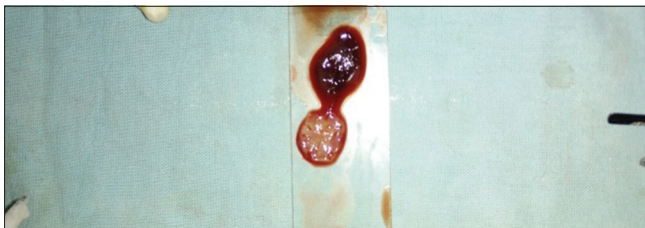


Figure 6: Platelet-rich fibrin membrane

Socket preservation procedures are used widely to manage the tissue dimensional alterations after tooth removal. These techniques are considered as predictable procedures to reduce the need for extensive bone augmentation operations in implant dentistry. There are different socket/ridge preservation techniques with different outcomes. Furthermore, there is no evidence to support the superiority of one specific technique over another.¹⁶ Our recommended technique, named CGFST, would be useful in high esthetic demand cases due to its ability to enhance healing and lower or stabilize bone resorption.




Figure 7: Platelet-rich fibrin with tri calcium phosphate graft

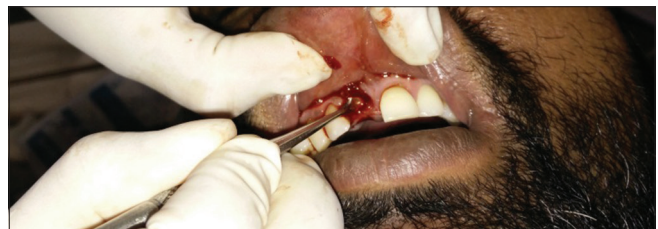

Figure 8: Sandwich technique-platelet-rich fibrin

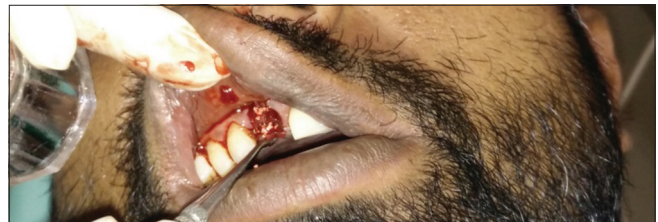

Figure 9: Sandwich technique-platelet-rich fibrin with graft

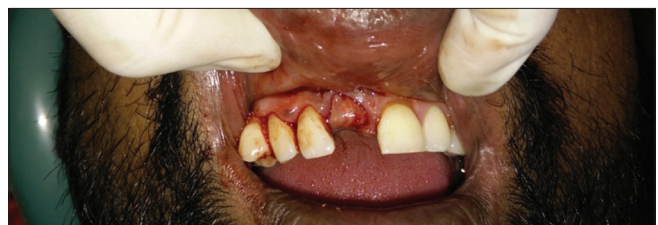

Figure 10: Sandwich technique-platelet-rich fibrin membrane

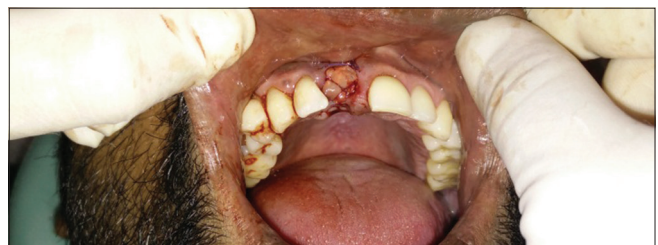

Figure 11: Cross-over sutures

An article published by Araujo, in 2009, demonstrated that the placement of a biomaterial in an extraction

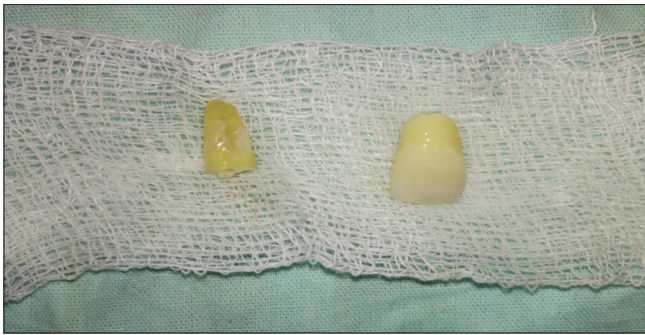


Figure 12: Crown separated from root

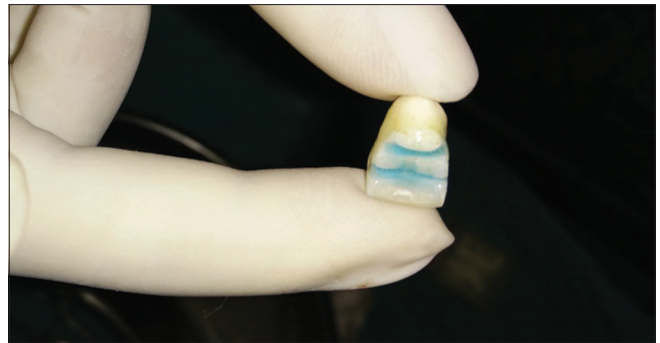


Figure 16: Etching and bonding of wire

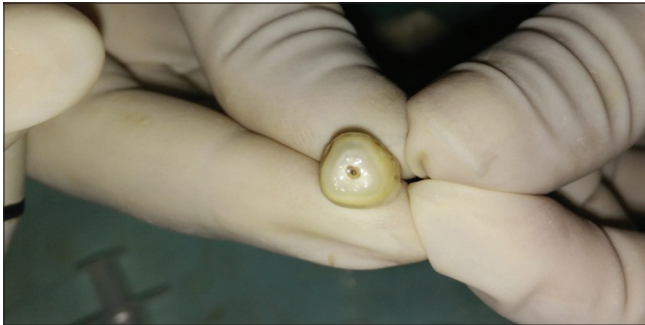

Figure 13: Pulp extirpated

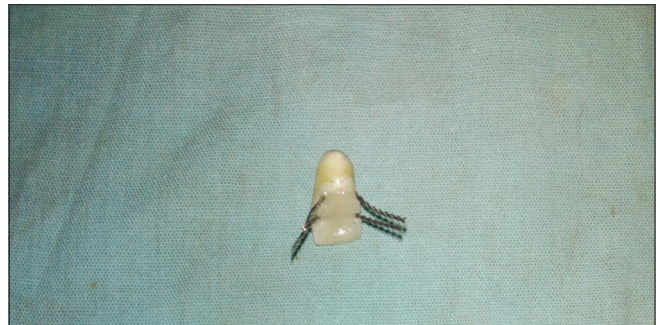


Figure 17: Prepared pontic

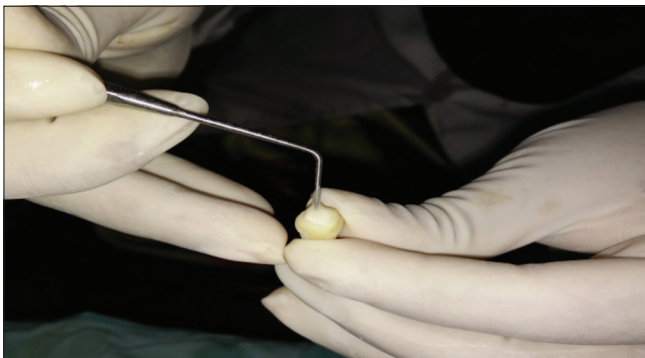


Figure 14: Pulp canal sealed

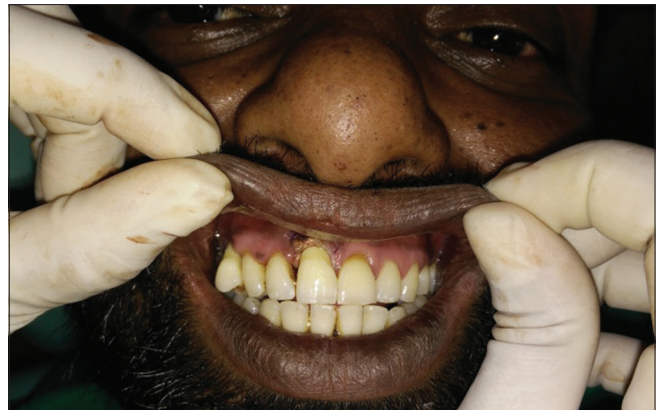

Figure 18: Immediate final restoration (frontal view)

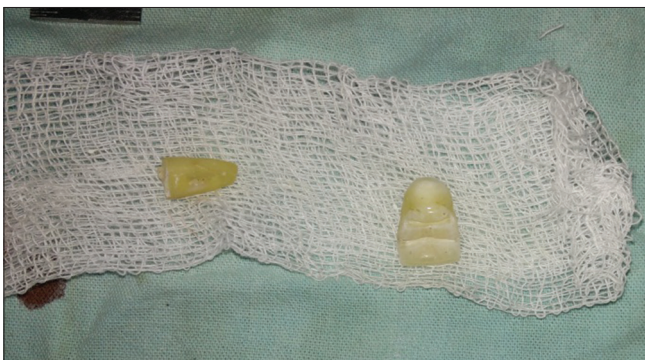


Figure 15: Tooth prepared with grooves

socket enhances bone modeling and compensates the marginal ridge contraction.¹⁷ Alloplasts, such as β TCP, have demonstrated potential in surgical

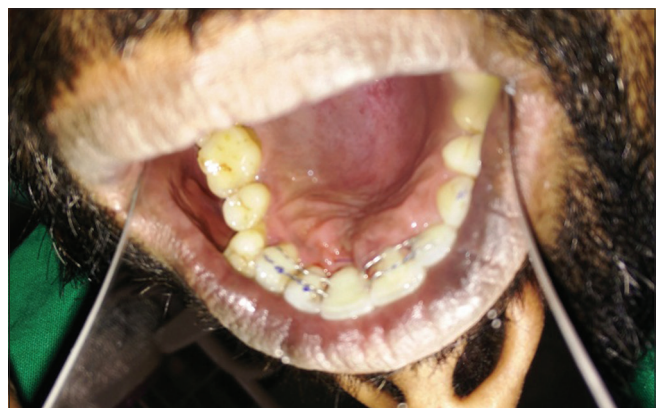

Figure 19: Immediate final restoration (occlusal view)

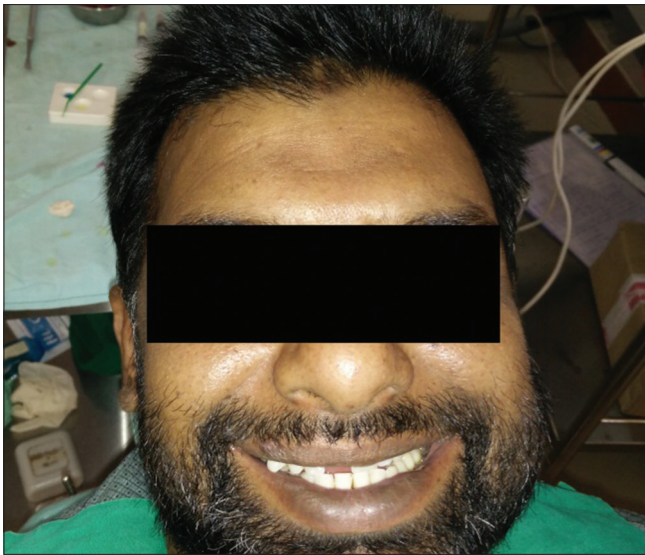

Figure 20: Post-extraction

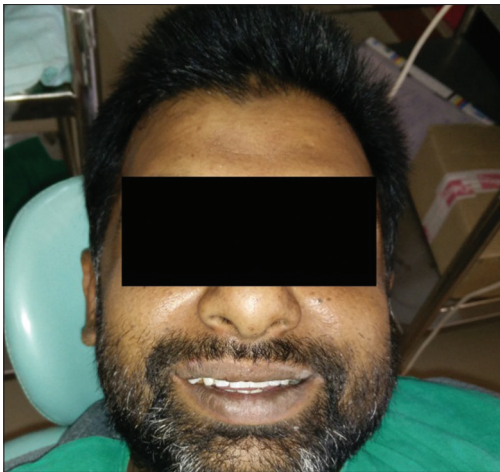

Figure 21: Post-operative (after socket preservation and placement of natural tooth pontic)

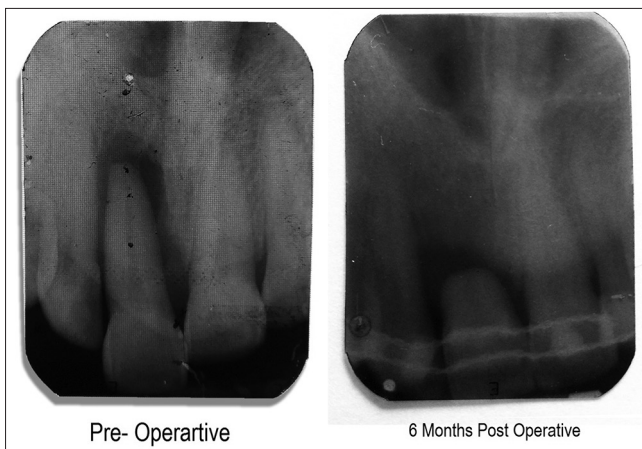

Figure 22: Pre and post operative IOPAR of the patient

therapy. It has been found to be biocompatible, biodegradable, osteoconductive, safe, and non-toxic. Its large granular inner surface area provides the highest

degree of osteoconductivity through clot stabilization, vascularization, cell adhesion, and penetration of host bone repair into the inner part of the graft material. Biphasic calcium phosphate enhances the biological resorption of the granule, ensures optimum bone in-growth and formation.¹⁸ As it undergoes degradation, it leaves behind a calcium phosphate trellis. Osteoblasts attach to it and start secreting the bone matrix.¹⁹

Furthermore, considerable interest has recently emerged over the potential benefits of using CGF/PRF, a highly concentrated form of platelets, packed with growth factors encased in a leukocyte rich matrix that enhances osteogenic differentiation and bone repair.²⁰ Simonprieri *et al.* summarized the advantages of PRF as it maintains and protects graft materials serving as a biologic connector between bone particles. It integrates fibrin network into the regenerative site and facilitates cellular migration (neo-angiogenesis). Moreover, platelet growth factors get released as fibrin network is resorbed over a period. Leukocytes in fibrin network play a role in self-regulation of inflammatory phenomenon of the graft material.²¹

There are various reasons why the surgeon may not wish to follow a particular treatment option. These reasons could also be viewed as limitations to socket preservation with bone grafting. Examples of potential problems are lack of adequate apical bone to begin with for primary anchorage of the implant; lack of buccal socket wall; the indications for immediate implant placement are stronger; lack of experience of the dentist in selecting appropriate materials and techniques; indecisive patient, etc. Regardless of the reasons, there seems to be a consensus that preserving or reconstructing the extraction socket of a failed tooth according to the principles of guided bone regeneration enhances our ability to provide esthetically pleasing restorations to our patients without violating the predictability and function of the prostheses.⁶

Considering these facts, we have done socket preservation using a combination of only CGF/PRF at the apical third, then CGF/PRF plus graft material to fill the remaining socket and finally covered the socket with a CGF/PRF membrane. This technique offers the dual advantage of maintaining soft and hard tissue contours as well as augmenting bone with the help of autologous PRF and bone stimulating grafting material, i.e. β tricalcium phosphate. The CGF/PRF at the apical third and the CGF/PRF mixed with bone graft in the remaining part of the socket plays a synergistic role during the resorption of calcium phosphate. The continuous supply of growth factors in the entire socket enhances formation of bone by osteoblasts. Apart from this, the resorbable biomembrane (CGF/PRF) that is placed at socket orifice helps to

not only contain the graft material but also possesses adequate cell occlusiveness to promote osteoblastic proliferation while simultaneously preventing gingival epithelial cell invasion and soft tissue migration into the socket.²²

The next logical step would be to speculate about the replacement options for the single tooth edentulous space that could be conventional fixed partial dentures, a removable partial denture and a single tooth implant.²³ The development of implants-supported restorations has led to a more conservative approach to a single tooth replacement, with improved psychological health, regained proprioception (occlusal awareness), increased stability, retention, phonetics and improved function, in comparison to the conventional FPDs that require aggressive tooth reduction during the preparation of abutment teeth with a high risk of pulp exposure²⁴ or RPDs that pose a problem of residual ridge resorption and deterioration of periodontal health of adjacent teeth.

The success of osseointegrated dental implants depends on whether there is a sufficient volume of healthy bone at the recipient site at the time of implant placement. The placement of an implant at a site with a thin crestal ridge (e.g. post extraction ridge) could result in a significant buccal dehiscence. Thus, it seems prudent to prevent alveolar ridge destruction and make efforts to preserve it during extraction procedures.⁶

Therefore, the best and feasible option to temporarily restore the edentulous space after extraction of a periodontally compromised tooth would be to replace it with the patient's own tooth in the form of wire retained resin bonded NTP.

In addition to the ease of usage and almost no adaptability period, NTPs achieve favorable esthetics, have a positive psychological effect on the patient, allow for same visit tooth replacement, avoid laboratory work, and it is a reversible technique allowing other definitive restorative options to be evaluated. Furthermore, the micro-resiliency and ovate design of the pontic stimulates underlying tissue, avoids excessive post extraction ridge resorption, and contouring of soft tissue architecture.²⁵

This procedure is also associated with a number of limitations such as relying on patient's motivation and manual dexterity to maintain oral hygiene around the pontic, limited functional efficiency, irritation to the tongue and chances of splint breakage.¹⁵ Among these limitations, bonding of the NTP to the adjacent teeth is crucial and extremely important for the success of such conservative bridges. The predominant location of debonding with resin bonded fixed partial dentures is between the luting cement and the framework of the

denture.²⁶ In this case, good adhesion was ensured by incorporating two palatal grooves and splinting the NTP to two adjacent teeth on either side (instead of just one groove and one additional tooth on either side). The proposed new technique provides optimum stability of the pontic around all axes of rotation, greater durability, and enhanced retention, which may not be obtained with a single groove.

Replacement with NTP is technically demanding and cannot be used for every patient. Some key factors need to be considered before performing such restorations, such as:

- Patient's bite
- Any interfering parafunctional habits
- Inadequate occlusal clearance space for the wire composite bonding
- Inability to maintain isolation of field during bonding procedures
- Primary dentition.²⁷⁻²⁹

Despite such restrictions, this technique of using NTP has been tested by various researchers earlier and shown very satisfying results.³⁰⁻³² Even in this case, a 9-month follow-up demonstrated good clinical success. Complications, such as postoperative sensitivity, caries, de-bonding, and fracture at the connector area and discoloration, were not observed. However, efforts in preserving the gingival papilla by immediately placing an ovate pontic in the extraction area were not achieved likely due to preexisting periodontitis. Nevertheless, NTP has been successfully used as a temporary restoration until implant placement, and also, the same NTP can be used as a provisional prosthesis during the two-stage implant procedure.

CONCLUSION

Loss of teeth due to caries or traumas, often result in hard and soft tissue collapse, therefore, preserving or reconstructing the extraction socket of a failed tooth according to the principles of guided bone regeneration and socket preservation enhances our ability to provide adequate bone volume and esthetically pleasing restorations to our patients without violating the predictability and function of those prostheses. In recent years, the desire expressed by many patients for cosmetic and esthetic restorations is on a rise. Hence, the described technique using patient's natural tooth as a pontic is a conservative, esthetic, and cost-effective method for the replacement until future implant therapy.

This technique of socket preservation along with the NTP enables favorable architecture of the alveolar ridge with replacement of the original tooth, together with esthetics and functionality to a certain extent. However, additional

studies are necessary to provide more clinical data to draw further conclusions regarding this therapeutic approach.

ACKNOWLEDGMENT

We thank the Mr. Hafizulla for allowing us to share his details.

REFERENCES

1. Strassler HE. Single visit natural tooth pontic bridge with fiber reinforcement ribbon. *Australas Dent Pract* 2010;158-166.
2. Kretzschmar JL. The natural tooth pontic: A temporary solution for a difficult esthetic situation. *J Am Dent Assoc* 2001;132:1552-3.
3. Mecal RA, Rosenfeld AL. Influence of residual ridge resorption patterns on implant fixture placement and tooth position 1. *Int J Periodontics Restorative Dent* 1991;11:8-23.
4. Darby I, Chen ST, Buser D. Ridge preservation techniques for implant therapy. *Int J Oral Maxillofac Implants* 2009;24:260-71.
5. Lekovic V, Camargo PM, Klokkevold PR, Weinlaender M, Kenney EB, Dimitrijevic B, *et al.* Preservation of alveolar bone in extraction sockets using bioresorbable membranes. *J Periodontol* 1998;69:1044-9.
6. Irinakis T. Rationale for socket preservation after extraction of a single-rooted tooth when planning for future implant placement. *J Can Dent Assoc* 2006;72:917-22.
7. Paul L, Child Jr, Christensen GJ. Extract and graft or extract and dismiss? 2011. p. 28-34. <http://www.dentaltown.com/dentaltown/article.aspx?aid=3429>.
8. Elian N, Cho SC, Froum S, Smith RB, Tarnow DP. A simplified socket classification and repair technique. *Pract Proced Aesthet Dent* 2007;19:99-104.
9. Mohan R, Jain R, Amaranath BJ, Krishna MK. Natural tooth pontic: Single visit fibre reinforced splinting. *J Adv Med Dent Sci* 2013;1:144-6.
10. Arteaga S, Meiers JC. Single-tooth replacement with a chairside prefabricated fiber-reinforced resin composite bridge: A case study. *Gen Dent* 2004;52:517-9.
11. Kermanshah H, Motevasselian F. Immediate tooth replacement using fiber-reinforced composite and natural tooth pontic. *Oper Dent* 2010;35:238-45.
12. Stumpel LJ 3rd. The natural tooth pontic; Simplified. *J Calif Dent Assoc* 2004;32:257-60.
13. Freilich MA, Meiers JC, Duncan JP, Goldberg AJ. *Fiber Reinforced Composites in Clinical Dentistry*. Chicago: Quintessence; 2000. p. 57.
14. Purra AR, Mushtaq M. Aesthetic replacement of an anterior tooth using the natural tooth as a pontic; An innovative technique. *Saudi Dent J* 2013;25:125-8.
15. Bhandari S, Chaturvedi R. Immediate natural tooth pontic: A viable yet temporary prosthetic solution: A patient reported outcome. *Indian J Dent Res* 2012;23:59-63.
16. Gholami GA, Aghaloo M, Ghanavati F, Amid R, Kadkhodazadeh M. Three dimensional socket preservation: A technique for soft tissue augmentation along with socket grafting. *Ann Surg Innov Res* 2012;6:3.
17. Araújo MG, Lindhe J. Ridge alterations following tooth extraction with and without flap elevation: An experimental study in the dog. *Clin Oral Implants Res* 2009;20:545-9.
18. Kaushik BT, Jayakumar ND, Padmalatha O, Varghese S. Treatment of human intra bony periodontal defects with hydroxyapatite + β tricalcium phosphate bone graft alone and in combination with platelet rich plasma: A randomized controlled trial. *Indian J Dent Res* 2011;22:505-10.
19. Arts JJ, Walschot LH, Verdonschot N, Schreurs BW, Buma P. Biologic activity of tri calcium phosphate/hydroxyapatite granules mixed with impacted morsellized bone graft. A study in Rabbits. *J Biomed Mater Res B Appl Biomater* 2007;81:476-85.
20. Gupta HS, Chowdhary KY, Pathak TS, Kini VV, Pereira R, Mistry A. Socket preservation at molar site using platelet rich fibrin and bio-ceramics for implant site development. *J Contemp Dent* 2013;3:102-7.
21. Simonpieri A, Del Corso M, Sammartino G, Dohan Ehrenfest DM. The relevance of Choukroun's platelet-rich fibrin and metronidazole during complex maxillary rehabilitations using bone allograft. Part II: Implant surgery, prosthodontics, and survival. *Implant Dent* 2009;18:220-9.
22. Cardaropoli D, Tamagnone L, Roffredo A, Gaveglia L, Cardaropoli G. Socket preservation using bovine bone mineral and collagen membrane: A randomized controlled clinical trial with histologic analysis. *Int J Periodontics Restorative Dent* 2012;32:421-30.
23. Corrente G, Vergnano L, Re S, Cardaropoli D, Abundo R. Resin-bonded fixed partial dentures and splints in periodontally compromised patients: A 10-year follow-up. *Int J Periodontics Restorative Dent* 2000;20:628-36.
24. Goodacre CJ, Bernal G, Rungcharassaeng K, Kan JY. Clinical complication in fixed prosthodontics. *J Prosthet Dent* 2003;90:31-41.
25. Parolia A, Shenoy KM, Thomas MS, Mohan M. Use of a natural tooth crown as a pontic following cervical root fracture: A case report. *Aust Endod J* 2010;36:35-8.
26. Hussey DL, Pagni C, Linden GJ. Performance of 400 adhesive bridges fitted in a restorative dentistry department. *J Dent* 1991;19:221-5.
27. Belli S, Ozer F. A simple method for single anterior tooth replacement. *J Adhes Dent* 2000;2:67-70.
28. Stein RS. Pontic-residual ridge relationship: A research report. *J Prosthet Dent* 1966;16:251-85.
29. Edelhoff D, Spiekermann H, Yildirim M. A review of esthetic pontic design options. *Quintessence Int* 2002;33:736-46.
30. Giordano R 2nd. Fiber reinforced composite resin systems. *Gen Dent* 2000;48:244-9.
31. Rada RE. Mechanical stabilization in the mandibular anterior segment. *Quintessence Int* 1999;30:243-8.
32. Walsh LJ, Liew VP. The natural tooth pontic – A compromise treatment for periodontally involved anterior teeth. *Aust Dent J* 1990;35:405-8.

How to cite this article: Hemalata M, Jayanthi D, Vivekanand L, Shafi GA, Keerti V. Sandwich Technique of Socket Preservation using Concentrated Growth Factor and Tricalcium Phosphate and an Immediate Interim Prosthesis with a Natural Tooth Pontic: A Case Report. *Int J Adv Health Sci* 2016;2(10):18-25.

Source of Support: Nil, **Conflict of Interest:** None declared.