



# Removal of Displaced Foreign Body From the Maxillary Sinus Using Replaceable Bony Windows and Saline Irrigation, Followed by Suctioning of the Foreign Body

Dong-Seok Sohn, DDS, PhD,\* Heui-Seung Jung, DDS,† Ki-Hyun Kim, DDS,‡ Kyung-Jin Song, DDS,§ Hee-Won An, DDS,|| and Kyung-Ho Min, DDS¶

A foreign body can be displaced into the maxillary sinus during dental surgery. Dental implants can migrate into the maxillary sinus due to poor bone density and/or poor initial stability in the posterior maxilla.<sup>1</sup> Other foreign bodies, such as tooth roots or metallic objects, can migrate into the sinus due to the doctor's inexperience.<sup>2-4</sup> Migrated foreign bodies in the sinus can cause significant complications such as inflammatory reactions, sinusitis, and fungal infections,<sup>5-8</sup> and the dental implant can be displaced into the sphenoidal sinus.<sup>9</sup> To extract displaced foreign bodies from the sinus, the Caldwell-Luc ap-

*Various surgical techniques for the removal of a foreign body from maxillary sinuses have been reported. However, the access window in the lateral wall of the maxillary sinus cavity is not replaced by a bony wall when sinus grafting is not performed. The replaceable bony window provides an access window into the sinus cavity and maintains the integrity of the lateral wall of the sinus cavity after the removal*

*of a foreign body from the sinus. Saline irrigation and suction are simple and quick techniques to remove foreign bodies from the sinus. This technique does not require special equipment, including that of endoscopy. (Implant Dent 2011;20:1-000)*

**Key Words:** *displaced foreign body, replaceable bony window, sinus graft, ultrasonic piezoelectric bone surgery, platelet-rich fibrin block*

proach or the lateral window approach, combined with endoscopic surgery, antrally or transnasally, have been reported.<sup>5-11</sup> However, when the Caldwell-Luc or lateral window approach is performed without a sinus graft, the access window may not be replaced by a new bony wall in the lateral wall of the sinus.<sup>12,13</sup> To remove foreign bodies, the use of endoscopy is definitely effective; but this procedure, which requires specific training and equipment, has some disadvantages.<sup>11</sup> The aim of this report is to present a simple procedure to remove a foreign body using saline irrigation and suctioning of the foreign body from the sinus, and how to maintain the integrity of the lateral wall of the maxillary sinus using a replaceable bony window after the removal of foreign body.

## CASE REPORT 1

A 27-year-old man was referred, by his family dentist, to the Depart-

ment of Oral and Maxillofacial Surgery, Catholic Medical Center of Daegu, for the removal of a tooth root that intruded into the maxillary sinus. The root was displaced by improper manipulation of an elevator during the extraction of a severely decayed right maxillary second premolar. Radiographic examination showed the displaced tooth root in the sinus (Fig. 1). The patient did not complain of any problems associated with the sinus. The patient was scheduled to have the intruded root removed using a replaceable bony window. A sinus graft was not planned. Prophylactic Flumoxef sodium (Flumarin; Ildong Pharmaceutical Co., Korea, 500 mg iv) was administered 1 hour before surgery on April 5, 2007. After the administration of a local anesthetic solution (2% lidocaine with 1:100,000 epinephrine), a vestibular incision was made, and the mucoperiosteal flap was elevated to expose the lateral wall of the max-

\*Chairman and Professor, Department of Dentistry and Oral and Maxillofacial Surgery, Daegu Catholic University Hospital, Daegu, Republic of Korea.

†Clinical Professor, Department of Dentistry and Oral and Maxillofacial Surgery, Daegu Catholic University Hospital; Private Practice, Seo-Mun Dental Clinic, Daegu, Republic of Korea.

‡Clinical Professor, Department of Dentistry and Oral and Maxillofacial Surgery, Daegu Catholic University Hospital; Private Practice, Goodwill Dental Hospital, Busan, Republic of Korea.

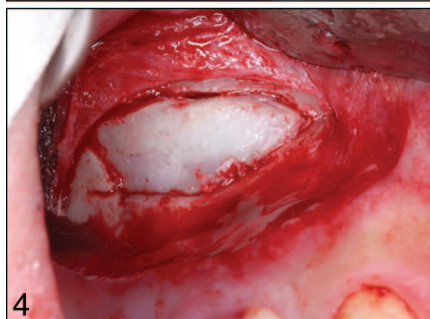
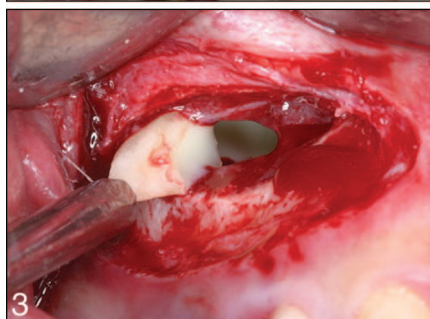
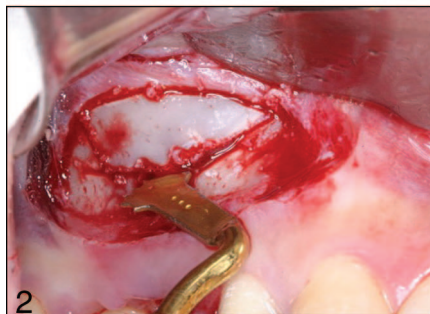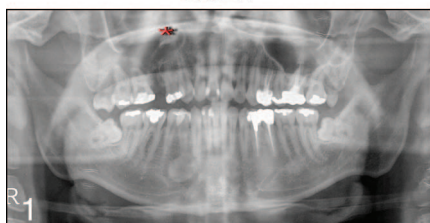
§Clinical Professor, Department of Dentistry and Oral and Maxillofacial Surgery, Daegu Catholic University Hospital; Private Practice, Susung Union Dental Clinic, Daegu, Republic of Korea.

||Clinical Professor, Department of Dentistry and Oral and Maxillofacial Surgery, Daegu Catholic University Hospital; Private Practice, Neul Gippen Dental Clinic, Seoul, Republic of Korea.

¶Clinical Professor, Department of Dentistry and Oral and Maxillofacial Surgery, Daegu Catholic University Hospital; Private Practice, Sung Shim Bubu Dental Clinic, Daegu, Republic of Korea.

Reprint requests and correspondence to: Dong-Seok Sohn, DDS, PhD, Department of Oral and Maxillofacial Surgery, Daegu Catholic University Hospital, 3056-6 Daemyung 4-Dong, Nam-Gu, Daegu 705-034, Republic of Korea, Phone: (53) 650-4288, Fax: (53) 622-7067, E-mail: dssohn@cu.ac.kr

## CASE 1



**Fig. 1.** Radiogram showing residual root in the right maxillary sinus.

**Fig. 2.** Tilted osteotomy was performed to make a replaceable bony window using a piezoelectric saw insert.

**Fig. 3.** The root was suctioned with a saline flow by an aspirator.

**Fig. 4.** Note the precisely repositioned bony window.

illary sinus. A saw insert with a thin blade (S-Saw, Bukboo Dental Co., Daegu, Korea), connected to an ultrasonic piezoelectric device (Surgybone, Silfradent srl, Sofia, Italy), was used to make the replaceable bony window. The inferior osteotomy was made 2 to 3 mm above the sinus floor and the anterior vertical osteotomy was made

2 mm distal to the anterior vertical wall of the maxillary sinus. Both osteotomies were created perpendicularly to the inside of the maxillary sinus lateral wall to facilitate the precise replacement of the bony window after removal of the foreign body from the sinus. The distal osteotomy was made approximately 15 mm away from the anterior vertical osteotomy. The height of the vertical osteotomy was approximately 10 mm (Fig. 2). The bony window was detached carefully to expose the sinus membrane. An approximately 1-cm long incision was made through the sinus membrane. The suction apparatus was intruded into the sinus, and normal saline was injected into the sinus cavity at the same time. The root, floating in the saline flow, was removed by suction within 1 minute (Fig. 3) After the removal of the root, the bony portion of lateral window was repositioned (Fig. 4). Flaps were sutured using PTFE sutures (Cytoplast, Osteogenic Biomedical, Texas, USA) to achieve passive primary closure. Postoperative Cefditoren pivoxil (Meiact; Boryung Pharm., Seoul, Korea) 300 mg three times per day was used for 7 days and the sutures were removed 10 days postoperatively.

### CASE REPORT 2

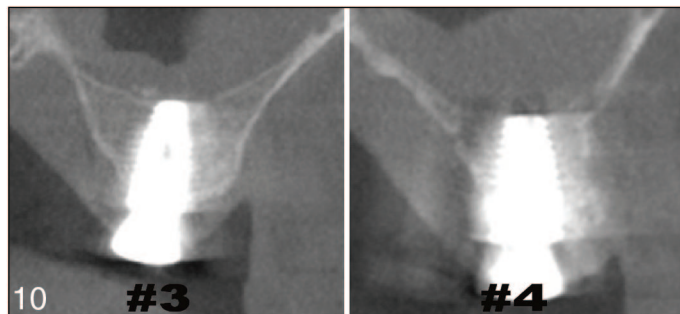
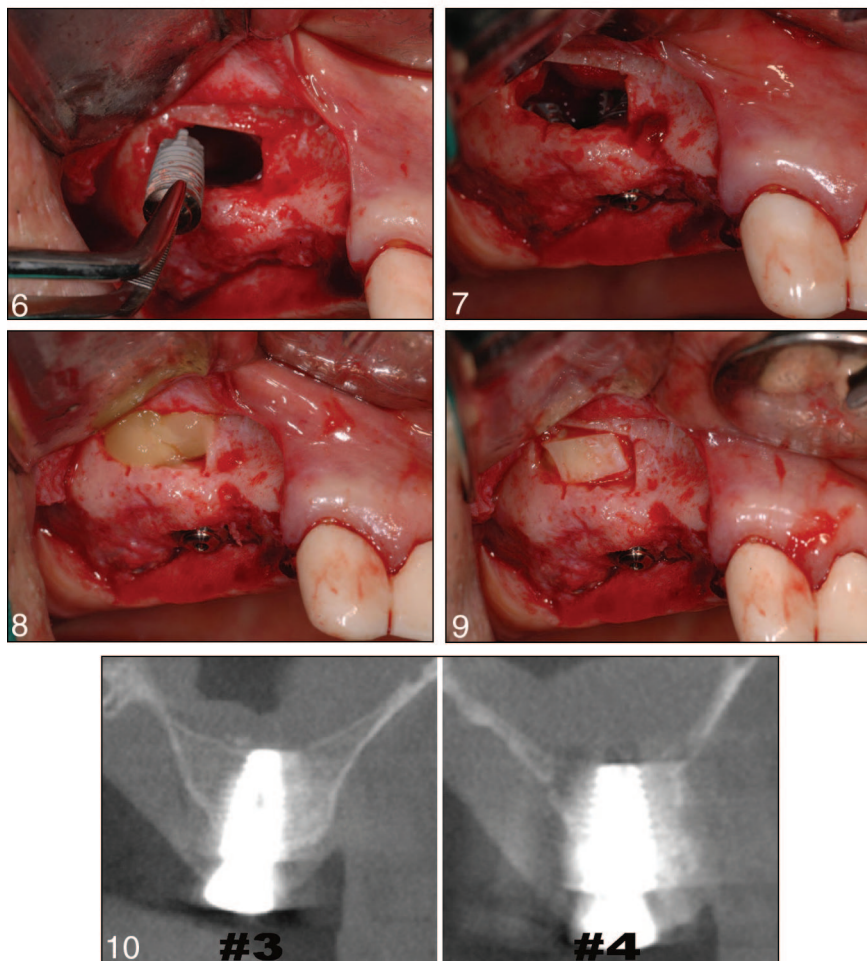
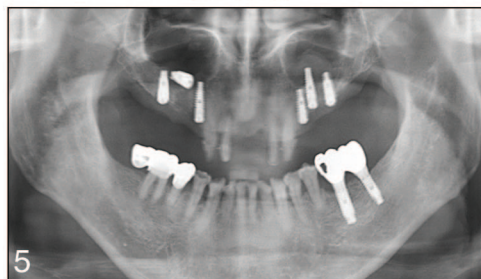
A male patient, aged 42 years, was referred to our Department for the removal of an intruded implant in the sinus. Crestally approached sinus augmentation and simultaneous implant placement was performed at sites 3, 4, and 5 by a private practitioner on March 18, 2009. The implant was stable at the time of surgery, but 3 months postoperatively, a radiogram revealed intrusion at implant site 4 (Fig. 5). The cause of the implant intrusion seems to be the perforation of the sinus membrane, according to our careful examination of a postoperative cone beam CT scan. The same surgical procedure as seen in case report 1 was performed to remove the intruded implant from the sinus. The implant was suctioned to the lateral window and picked up with a dental pincette (Fig. 6). The sinus membrane was elevated carefully, and the surface of the site 4 implant was exposed. The mem-

brane elevation was extended over the site 3 implant. Colla tape was adapted to seal the membrane perforation, and a 5.0-mm wide implant (Uni implant System, Busan, Korea) was placed simultaneously at site 4 (Fig. 7). Four pieces of platelet-rich fibrin block with concentrated growth factors were made by special centrifugation (Medifuge, Silfradent srl, S.Sofia, Italy), and inserted into the new compartment of the sinus as an alternative to bone grafting (Fig. 8). The bony portion of the window was replaced and the flaps were sutured using PTFE sutures (Fig. 9). Implants were uncovered, at a private practice, after 6 months of healing and all implants were stable. Cone beam CT scans revealed bone formation at sites 3 and 4 in the sinuses (Fig. 10).

### DISCUSSION

The displacement of a foreign body into sinuses is a common complication. Displaced foreign bodies can cause serious complications if not removed from the sinus.<sup>6-11</sup> Various surgical methods for the retrieval of foreign bodies have been reported.<sup>1-11</sup> The Caldwell-Luc approach, the lateral window approach, or endoscopic transantral/transnasal surgery are commonly used procedures for the retrieval of foreign bodies. The Caldwell-Luc approach has some disadvantages such as postoperative numbness, paresthesia, facial asymmetry, and dental problems.<sup>14,15</sup> The lateral window approach provides better direct vision to verify the foreign body in the sinus than an approach through the alveolar socket, and sinus bone grafting could be followed after the removal of the foreign body from the sinus. However, the lateral window or Caldwell-Luc approach for the retrieval of a foreign body violates the integrity of the lateral wall of the sinus and the access window may not be replaced by a bony wall if the sinus bone graft is not performed at the same time (as shown after the classic Caldwell-Luc operation).<sup>12,13</sup> In addition, a sinus graft is not indicated in all patients after the removal of a foreign body from the sinus. Sinus grafting is

## CASE 2



**Fig. 5.** Radiogram showing the migrated implant into the sinus.  
**Fig. 6.** The implant was suctioned by aspirator and picked up with a dental pincette.  
**Fig. 7.** The placement of a wide body implant at site 4 after elevation of the sinus membrane.  
**Fig. 8.** A platelet-rich fibrin block with concentrated growth factors (CGF) was grafted under the elevated sinus membrane to accelerate new bone formation in the sinus.  
**Fig. 9.** The bony window was repositioned precisely into the access window.  
**Fig. 10.** Cone beam CT view showing bone formation at sites 3 and 4 after 6 months of healing.

bony window made by the piezoelectric saw insert with a thin blade is precisely repositioned, whether bone grafting in the sinus was performed, because of the tilted osteotomy into the sinus and the minimal bone loss during osteotomy.<sup>19,20</sup> The replaceable bony window acts as a homologous barrier over the bone graft in the sinus. Replaceable bony windows not only prevent soft tissue invasion into the grafted site as a barrier but also act as osteoinductive/osteoconductive substrates for new bone formation in the sinus and new bony wall in the lateral wall of sinus.<sup>19,20</sup> Previous studies reported the potency for new bone formation with replaceable bony windows in the maxillary sinus without bone grafts in humans.<sup>19,21</sup> Histological evidence to confirm new bone formation, in human sinuses, with replaceable windows and no bone grafts for sinus augmentation has been previously reported.<sup>19</sup> As an alternative to bone grafting for sinus augmentation, patient's blood, gelatin sponges, platelet-rich plasma, and platelet-rich fibrin blocks with concentrated growth factors grafted in the new compartment under the elevated sinus membrane has shown successful new bone formation in the sinus.<sup>22-26</sup> Endoscopic surgery is less invasive than the Caldwell-Luc approach and effectively verifies the presence of a foreign body in the sinus.<sup>7,10,11</sup> However, endoscopic surgery is limited to a specialist with special training, and requires special equipment.<sup>11</sup> Saline irrigation through a small incision site of sinus mucosa into the sinus cavity mobilizes displaced foreign bodies in the sinus, and a surgical suction apparatus aspirates the saline and foreign body at the same time. This technique is a simple and quick method to retrieve a foreign body out of the sinus, and does not require special instruments, as endoscopy does.

## CONCLUSION

Replaceable bony window regenerates new bony walls at the site of access windows, without additional sinus bone grafting, and maintains the integrity of the lateral wall of the maxilla after the removal of the foreign

contraindicated when the patients have a history of sinus-related pathology or severely perforated sinus membranes. In addition, except for displaced dental implants into the sinus, a bone graft is not required in most patients after the removal of a foreign body from the

sinus. The replaceable bony window maintains the integrity of the lateral wall of the sinus after the removal of the foreign body. A piezoelectric saw insert-assisted osteotomy has some advantages such as speed, precision, and minimal bone loss.<sup>16-18</sup> The lateral

body from the sinus. Saline irrigation into the sinus cavity and simultaneous suctioning of the foreign body, which does not require special equipment, is a less invasive and simpler method than endoscopy.

#### Disclosure

The authors claim to have no financial interest in any company or any of the products mentioned in this article.

#### REFERENCES

1. Iida S, Tanaka N, Kogo M, et al. Migration of a dental implant into the maxillary sinus. A case report. *Int J Oral Maxillofac Surg.* 2000;29:358-359.
2. Smith JL II, Emko P. Management of a maxillary sinus foreign body (dental bur). *Ear Nose Throat J.* 2007;86:677-678.
3. Dimitrakopoulos I, Papadaki M. Foreign body in the maxillary sinus: Report of an unusual case. *Quintessence Int.* 2008;39:698-701.
4. Sethi A, Cariappa KM, Chitra A. Root fragment in the ostium of the maxillary sinus. *Br J Oral Maxillofac Surg.* 2009;47:572-573.
5. Ueda M, Kaneda T. Maxillary sinusitis caused by dental implants: Report of two cases. *J Oral Maxillofac Surg.* 1992;50:285-287.
6. Macan D, Cabov T, Kobler P, et al. Inflammatory reaction to foreign body (amalgam) in the maxillary sinus misdiagnosed as an ethmoid tumor. *Dentomaxillofac Radiol.* 2006;35:303-306.
7. Selmani Z, Ashammakhi N. Surgical treatment of amalgam fillings causing iatrogenic sinusitis. *J Craniofac Surg.* 2006;17:363-365.
8. Burnham R, Bridle C. Aspergillosis of the maxillary sinus secondary to a foreign body (amalgam) in the maxillary antrum. *Br J Oral Maxillofac Surg.* 2009;47:313-315.
9. Felisati G, Lozza P, Chiapasco M, et al. Endoscopic removal of an unusual foreign body in the sphenoid sinus: An oral implant. *Clin Oral Implants Res.* 2007;18:776-780.
10. Ucer TC. A modified transantral endoscopic technique for the removal of a displaced dental implant from the maxillary sinus followed by simultaneous sinus grafting. *Int J Oral Maxillofac Implants.* 2009;24:947-951.
11. Nakamura N, Mitsuyasu T, Ohishi M. Endoscopic removal of a dental implant displaced into the maxillary sinus: Technical note. *Int J Oral Maxillofac Surg.* 2004;33:195-197.
12. Unger JM, Dennison BF, Duncavage JA, et al. The radiological appearance of the post-Caldwell-Luc maxillary sinus. *Clin Radiol.* 1986;37:77-81.
13. Ohba T, Morimoto Y, Nagata Y, et al. Comparison of the panoramic radiographic and CT features of post-Caldwell-Luc maxillary sinuses. *Dentomaxillofac Radiol.* 2000;29:280-285.
14. Murray JP. Complications after treatment of chronic maxillary sinus disease with Caldwell-Luc procedure. *Laryngoscope.* 1983;93:282-284.
15. DeFreitas J, Lucente FE. The Caldwell-Luc procedure: Institutional review of 670 cases: 1975-1985. *Laryngoscope.* 1988;98:1297-1300.
16. Sohn DS, Ahn MR, Lee WH, et al. Piezoelectric osteotomy for intraoral harvesting of bone blocks. *Int J Periodontics Restorative Dent.* 2007;27:127-131.
17. Lee HJ, Ahn MR, Sohn DS. Piezoelectric distraction osteogenesis in the atrophic maxillary anterior area: A case report. *Implant Dent.* 2007;16:227-234.
18. Sohn DS. *Color Atlas, Clinical Applications of Piezoelectric Bone Surgery.* Seoul: Kunja Publishing Co.; 2008:47-160.
19. Sohn DS, Lee JS, Ahn MR, et al. New bone formation in the maxillary sinus without bone grafts. *Implant Dent.* 2008;17:321-331.
20. Sohn DS, Moon JW, Lee HW, et al. Comparison of two piezoelectric cutting tips for lateral bony window osteotomy: A retrospective study of 127 consecutive cases. *Int J Oral Maxillofac Surg.* In press.
21. Lundgren S, Andersson S, Gualini F, et al. Bone reformation with sinus membrane elevation: A new surgical technique for maxillary sinus floor augmentation. *Clin Implant Dent Relat Res.* 2004;6:165-173.
22. Steigmann M, Garg AK. A comparative study of bilateral sinus lifts performed with platelet-rich plasma alone versus alloplastic graft material reconstituted with blood. *Implant Dent.* 2005;14:261-266.
23. Hatano N, Sennerby L, Lundgren S. Maxillary sinus augmentation using sinus membrane elevation and peripheral venous blood for implant-supported rehabilitation of the atrophic posterior maxilla: Case series. *Clin Implant Dent Relat Res.* 2007;9:150-155.
24. Moon JW, Moon KN, Sohn DS. New bone formation in the maxillary sinus with elevation of sinus membrane and graft of absorbable gelatin sponge: Case series reports. *Implantology.* 2008;12:46-53.
25. Sohn DS, Moon JW, Moon KN, et al. New bone formation in the maxillary sinus using only absorbable gelatin sponge. *J Oral Maxillofac Surg.* 2010;68:1327-1333.
26. Sohn DS, Moon JW, Moon YS, et al. The use of concentrated growth factors (CGF) for sinus augmentation. *J Oral Implant.* 2009;38:25-35.

## ID Abstract Translations

### GERMAN / DEUTSCH

**AUTOR(EN):** Dong-Seok Sohn, DDS, PhD, Heui-Seung Jung, DDS, Ki-Hyun Kim, DDS, Kyung-Jin Song, DDS, Hee-Won An, DDS, Kyung-Ho Min, DDS

**Entfernung verschobener Fremdkörper aus dem Oberkiefer-sinus unter Verwendung austauschbarer knöcherner Fenster und salzhaltiger Spülungen und anschließender Absaugung des Fremdkörpers**

**ZUSAMMENFASSUNG:** Es wurde bereits über verschiedene chirurgische Methoden zur Entfernung eines Fremdkör-

pers aus dem Sinus des Oberkiefers berichtet. Allerdings wird dabei das Zugangsfenster in der lateralen Wand der Sinushöhle im Oberkiefer nicht durch eine knöchernen Wand ersetzt, sofern keine Sinustransplantation durchgeführt wird. Das austauschbare knöchernen Fenster bietet ein Zugangsfenster in die Sinushöhle hinein und erhält die Integrität der lateralen Wand der Sinushöhle nach Entfernung des Fremdkörpers aus dem Sinus. Salzhaltige Spülungen und die Absaugung stellen einfache und schnelle Methoden da, um einen Fremdkörper aus dem Sinus zu entfernen. Diese Technik erfordert keine spezielle Ausrüstung, inklusive das einer Endoskopie.

**SCHLÜSSELWÖRTER:** verschobener Fremdkörper, austauschbares knöchernes Fenster, Sinustransplantat, Ultraschall-Piezoelektrische Knochengewebsschirurgie, Thrombozytreicher Fibrinblock

## SPANISH / ESPAÑOL

**AUTOR(ES):** Dong-Seok Sohn, DDS, PhD, Heui-Seung Jung, DDS, Ki-Hyun Kim, DDS, Kyung-Jin Song, DDS, Hee-Won An, DDS, Kyung-Ho Min, DDS

**Extracción de un cuerpo extraño desplazado en el seno del maxilar usando ventanas óseas reemplazables e irrigación salina, seguido por la aspiración del cuerpo extraño**

**ABSTRACTO:** Se han reconocido varias técnicas quirúrgicas para la eliminación de un cuerpo extraño de los senos maxilares. Sin embargo, la ventana de acceso en la pared lateral de la cavidad del seno maxilar no se reemplaza con una pared ósea cuando no se realiza el injerto del seno. La ventana ósea reemplazable ofrece una ventana de acceso a la cavidad del seno y mantiene la integridad de la pared lateral de la cavidad del seno luego de la extracción del cuerpo extraño del seno. La irrigación salina y aspiración son técnicas rápidas y simples para eliminar cuerpos extraños del seno. Esta técnica no requiere equipos especiales, incluso los de endoscopia.

**PALABRAS CLAVES:** Cuerpo extraño desplazado, ventana ósea reemplazable, injerto del seno, cirugía ósea con ultrasonido piezoeléctrico, bloque de fibrina rica en plaquetas

## PORTUGUESE / PORTUGUÊS

**AUTOR(ES):** Dong-Seok Sohn, Cirurgião-Dentista, PhD, Heui-Seung Jung, Cirurgião-Dentista, Ki-Hyun Kim, Cirurgião-Dentista, Kyung-Jin Song, Cirurgião-Dentista, Hee-Won An, Cirurgião-Dentista, Kyung-Ho Min, Cirurgião-Dentista

**Remoção de corpo estranho deslocado da cavidade maxilar usando-se janelas ósseas substituíveis e irrigação salina, seguidas por sucção do corpo estranho**

**RESUMO:** Diversas técnicas cirúrgicas para a remoção de um corpo estranho das cavidades maxilares foram relatadas. Contudo, a janela de acesso na parede lateral da cavidade maxilar não é substituída por uma parede óssea quando o enxertamento da cavidade não é realizado. A janela óssea substituível fornece uma janela de acesso à cavidade e mantém a integridade da parede lateral da cavidade após a remoção de um corpo estranho da cavidade. A irrigação salina e a sucção são técnicas simples e rápidas para remover corpos estranhos da cavidade. Essa técnica não exige equipamento especial, incluindo o da endoscopia.

**PALAVRAS-CHAVE:** corpo estranho deslocado, janela óssea substituível, enxerto da cavidade, cirurgia piezoelétrica ultrassônica do osso, bloco de fibrina rica em plaquetas

## RUSSIAN / РУССКИЙ

**АВТОРЫ:** Dong-Seok Sohn, доктор хирургической стоматологии, доктор философии, Heui-Seung Jung, доктор хирургической стоматологии, Ki-Hyun Kim, доктор хирургической стоматологии, Kyung-Jin Song, доктор хирургической стоматологии, Hee-Won An, доктор хирургической стоматологии, Kyung-Ho Min, доктор хирургической стоматологии

**Удаление смещенного инородного тела из верхнечелюстной пазухи, используя временные костные окна и ирригацию соевым раствором с последующим отсасыванием инородного тела**

**РЕЗЮМЕ.** Сообщалось о различных хирургических методах удаления инородных тел из верхнечелюстных пазух. В данном случае окно доступа в латеральной стенке верхнечелюстной пазухи не замещается костной стенкой, если не выполняется трансплантация в верхнечелюстной пазухе. Временное костное окно обеспечивает доступ в верхнечелюстную пазуху, и сохраняет целостность латеральной стенки верхнечелюстной пазухи после удаления инородного тела из верхнечелюстной пазухи. Технически процедура удаления инородного тела из верхнечелюстной пазухи с использованием ирригации соевым раствором и отсасывания проста и не занимает много времени. Эта методика не требует специального оборудования, в том числе эндоскопического.

**КЛЮЧЕВЫЕ СЛОВА:** смещенное инородное тело, временное костное окно, трансплантат в верхнечелюстной пазухе, ультразвуковая пьезоэлектрическая костная хирургия, фибрин с высоким содержанием тромбоцитов

## TURKISH / TÜRKÇE

**YAZARLAR:** Dong-Seok Sohn, DDS, PhD, Heui-Seung Jung, DDS, Ki-Hyun Kim, DDS, Kyung-Jin Song, DDS, Hee-Won An, DDS, Kyung-Ho Min, DDS

**Yenilenen kemiksel pencere, e serum fizyolojik irigasyonu, ve ardından emme kullanılarak maksiler sinüsten yabancı cisim çıkarılması**

**ÖZET:** Maksiler sinüslerden yabancı bir cismin çıkarılmasına ilişkin olarak çeşitli cerrahi teknikleri bildirilmiştir. Ancak, sinüste greft yapılmadığında maksiler sinüs boşluğunun yan duvarında açılan erişme penceresi kemik bir duvarla kapatılmaz. Kemik pencerenin tekrardan kapatılabilmesi, sinüs boşluğuna erişim sağladığı gibi sinüsten yabancı cisim çıkarıldıktan sonra sinüs boşluğunun yan duvarının bütünlüğünü de korur. Serum fizyolojik ile irigasyon ve emme, sinüsten yabancı cisimlerin çıkarılmasında kullanılan basit ve hızlı yöntemlerdir. Bu teknik, endoskopi de dahil olmak üzere özel ekipmanın kullanılmasını gerektirmez.

**ANAHTAR KELİMELEER:** Yabancı cisim çıkarılması, yenilenen kemik pencere, sinüs grefti, ultrasonik piezoelektrik kemik cerrahisi, trombositten zengin fibrin blok

## JAPANESE / 日本語

### 骨窓置換処置と生食注水法に続く異物吸引摘出処置で、上顎洞に迷入した異物除去

共同研究者氏名: ドン-セオク・ソン (Dong-Seok Sohn) DDS, PhD, हेуй-सेंग·jung (Heui-Seung Jung) DDS, 키-히윤·김 (Ki-Hyun Kim) DDS, 킁-진·송 (Kyung-Jin Song) DDS, 히-웁·안 (Hee-Won An) DDS, 킁-호·민 (Kyung-Ho Min) DDS

#### 研究概要:

上顎洞から異物を除去するためのさまざまな外科技術が報告されている。ただし上顎洞底挙上術を施術しない場合には、上顎洞腔側壁のアクセス骨窓は骨壁で置換されない。骨窓置換処置は上顎洞腔へのアクセス窓を提供し、さらに上顎洞腔から異物を除去した後にも上顎洞腔側壁の完全状態を維持する。生食注水法と吸引摘出法は上顎洞腔から異物を除去するためには簡単でしかも迅速な外科技術で、内視顕微鏡などの特別装置も不要である。

キーワード: 異物迷入、骨窓置換処置、上顎洞底挙上術、超音波ピエゾエレクトリック骨外科処置、多血小板フィブリンブロック

## CHINESE / 中国語

### 使用可置換骨窗和生理鹽水冲洗，然後進行抽吸，從上頰竇取出移位異物

作者: Dong-Seok Sohn, DDS, PhD, Heui-Seung Jung, DDS, Ki-Hyun Kim, DDS, Kyung-Jin Song, DDS, Hee-Won An, DDS, Kyung-Ho Min, DDS

#### 摘要:

目前有多種關於從上頰竇取出異物的外科手術技巧報告。不過，不進行竇移植時，就不會以骨壁取代上頰竇腔橫向壁的進入窗口。可置換骨窗提供進入竇腔的窗口，同時在從竇取出異物之後維持竇腔側向壁的完整性。生理鹽水灌洗和抽吸則是快速從竇取出異物的簡便方法。這項技巧不需要使用包括內視鏡等特殊儀器。

關鍵字: 位移異物、可置換骨窗、竇移植、超音波壓電骨外科手術、富血小板血漿纖維蛋白塊

## KOREAN / 한국어

### 대체가능 골창 및 식염수 관류 후 이물질 흡인을 이용한 상악동 전위 이물질 제거

저자: Dong-Seok Sohn, DDS, PhD, Heui-Seung Jung, DDS, Ki-Hyun Kim, DDS, Kyung-Jin Song, DDS, Hee-Won An, DDS, Kyung-Ho Min, DDS

#### 요약:

상악동 이물질 제거를 위한 다양한 수술기법이 보고되어왔다. 그러나, 상악동 강외측벽 접근창은 상악동 이식이 수행되지 않는 경우 골벽에 의해 대체되지 않는다. 대체가능 골창으로 상악동 강내 접근창이 제공되며, 상악동으로부터 이물질 제거 후 상악동 강외측벽의 완전성 유지가 가능해진다. 식염수 관류 및 흡인은 상악동으로부터 이물질을 제거하는 간단하고 신속한 방법이다. 이러한 기술은 내시경을 포함한 특별한 장비를 필요로 하지 않는다.

키워드: 전위 이물질, 대체가능 골창, 상악동 이식, 초음파 압전 골수술, 혈소판 풍부 섬유소 차단

## AUTHOR QUERIES

### AUTHOR PLEASE ANSWER ALL QUERIES

1

AQ1— Please confirm whether the short title is OK as given. Yes the tilte is okay to me.

AQ2— Please update Ref. 20.

---